

VESICULAR
ERUPTIONS OF THE
ORAL MUCOUSA

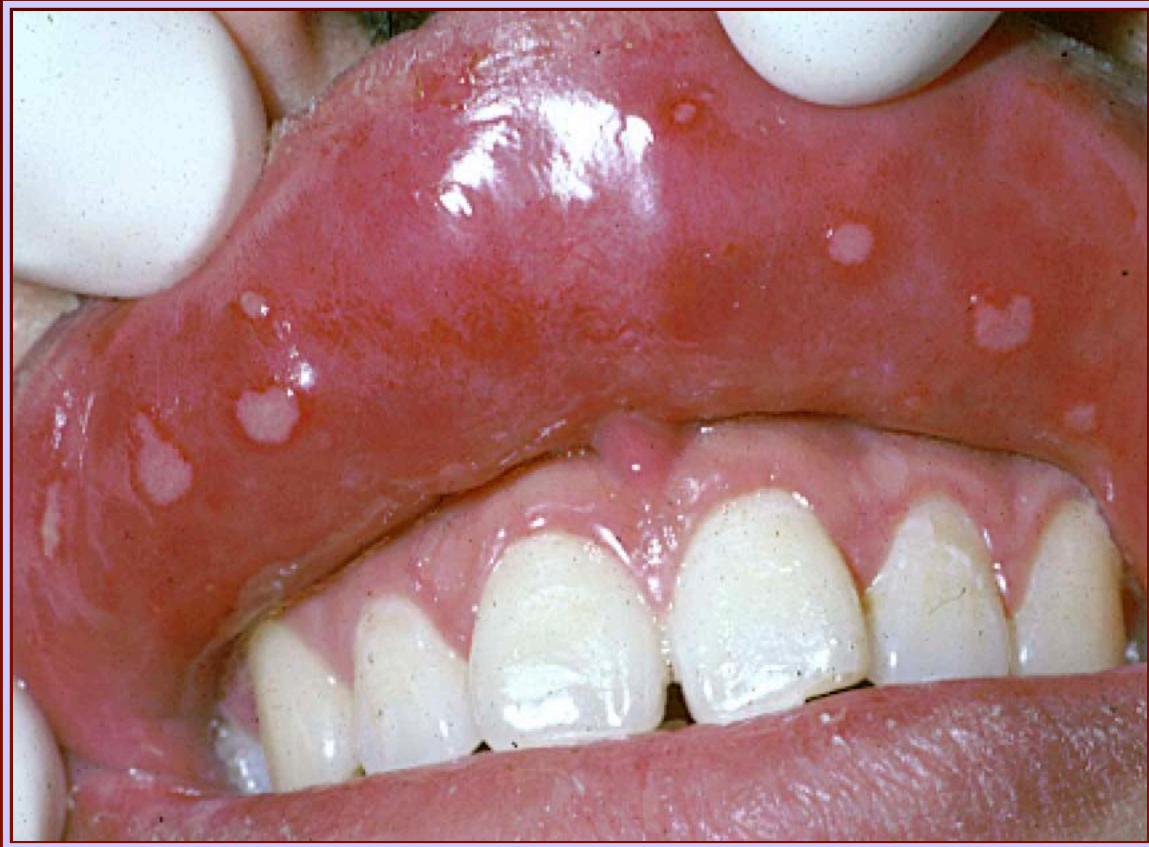Febrile Associated Vesicles

- Primary Herpetic Gingivostomatitis
- Varicella-Zoster
- Enterovirus stomatitis
- Hand Foot and Mouth Disease
- Herpangina

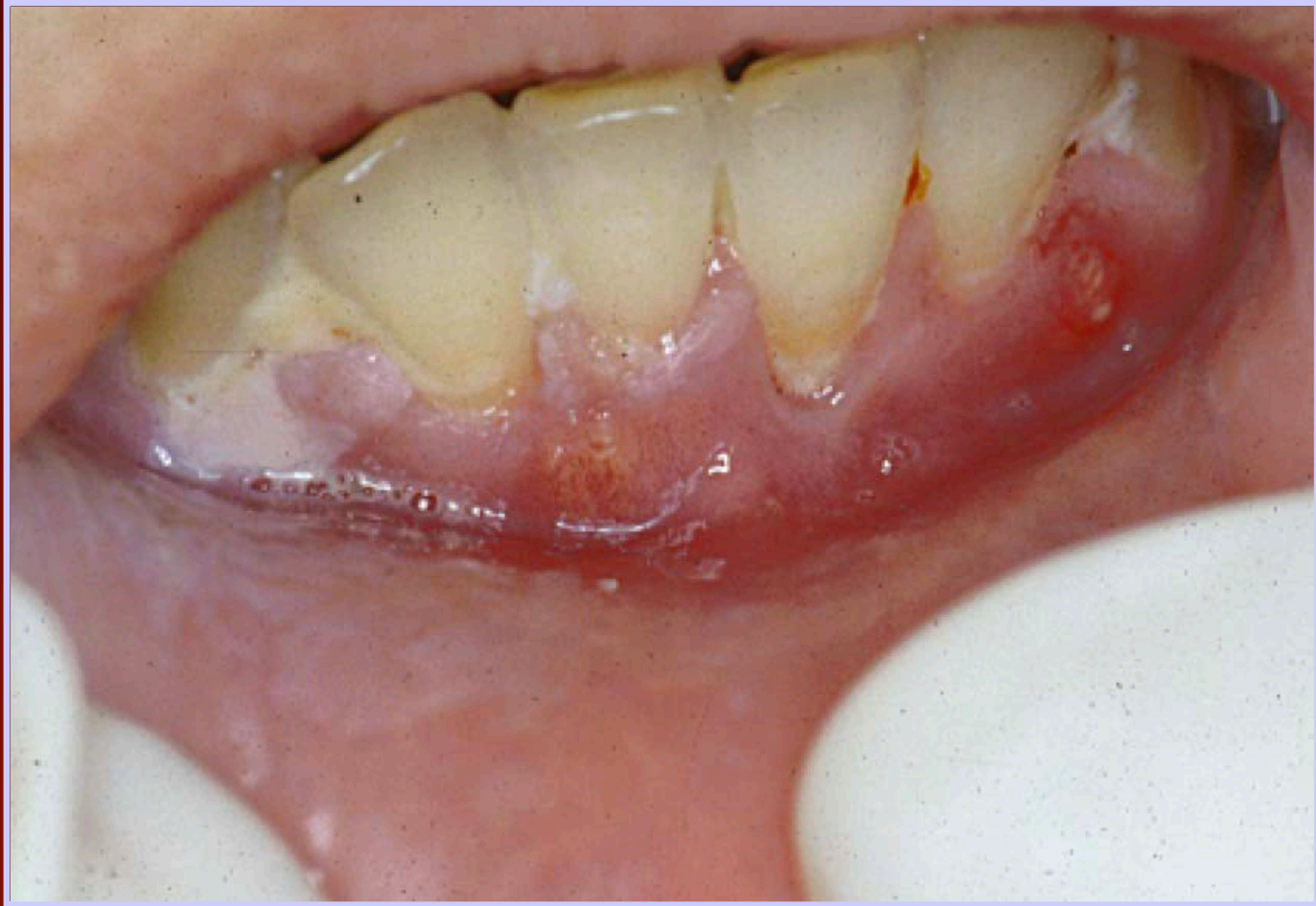Primary Herpetic Gingivostomatitis

- Childhood, Teens
- 99% of population, subclinical
- 1% of the population, Primary disease
- The “tetralogy” of signs and symptoms
 - Fever, lymphadenopathy, gingival lesions, movable mucosa lesions
- Infectious for 5 days, heal 7-8 days
- Robust immune response
- Establish latency in trigeminal ganglion
 - Both primary and subclinical infections

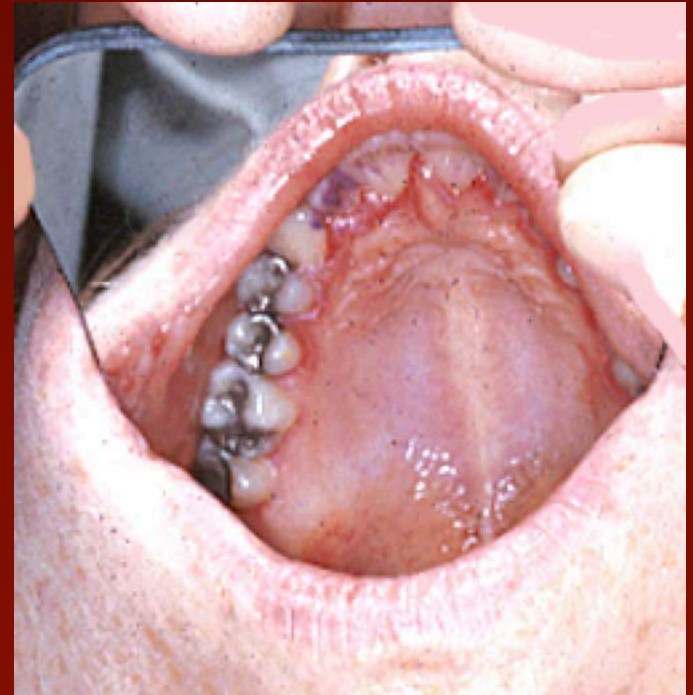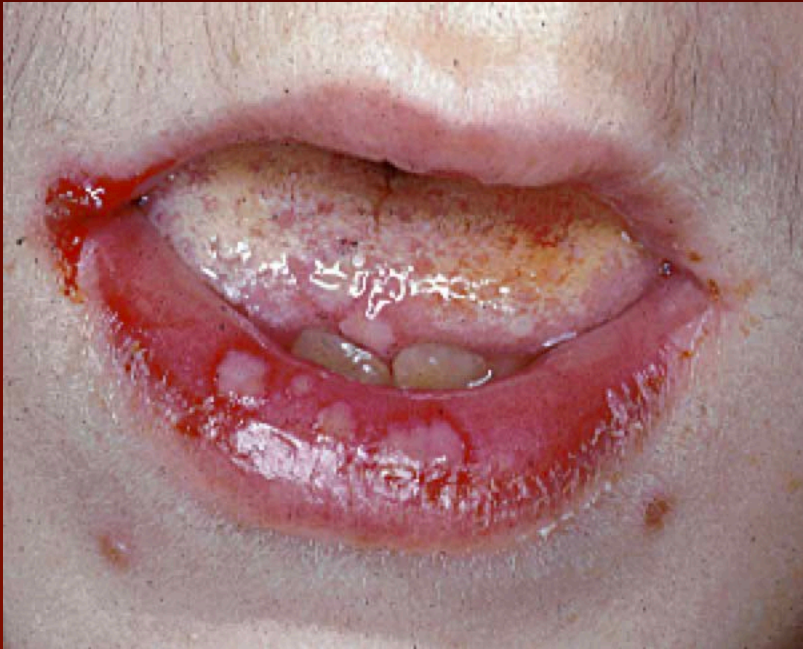Primary Herpetic Gingivostomatitis



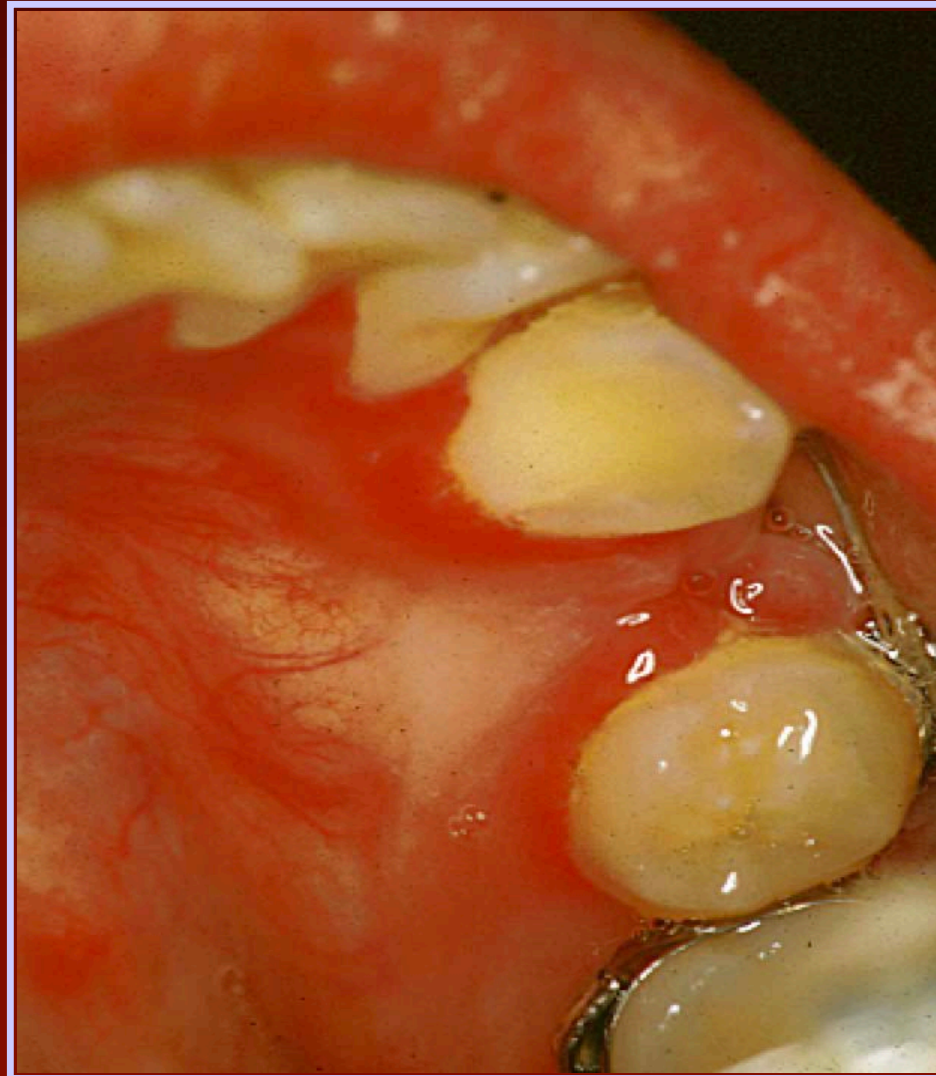
Primary Herpetic Gingivostomatitis



Primary Herpes

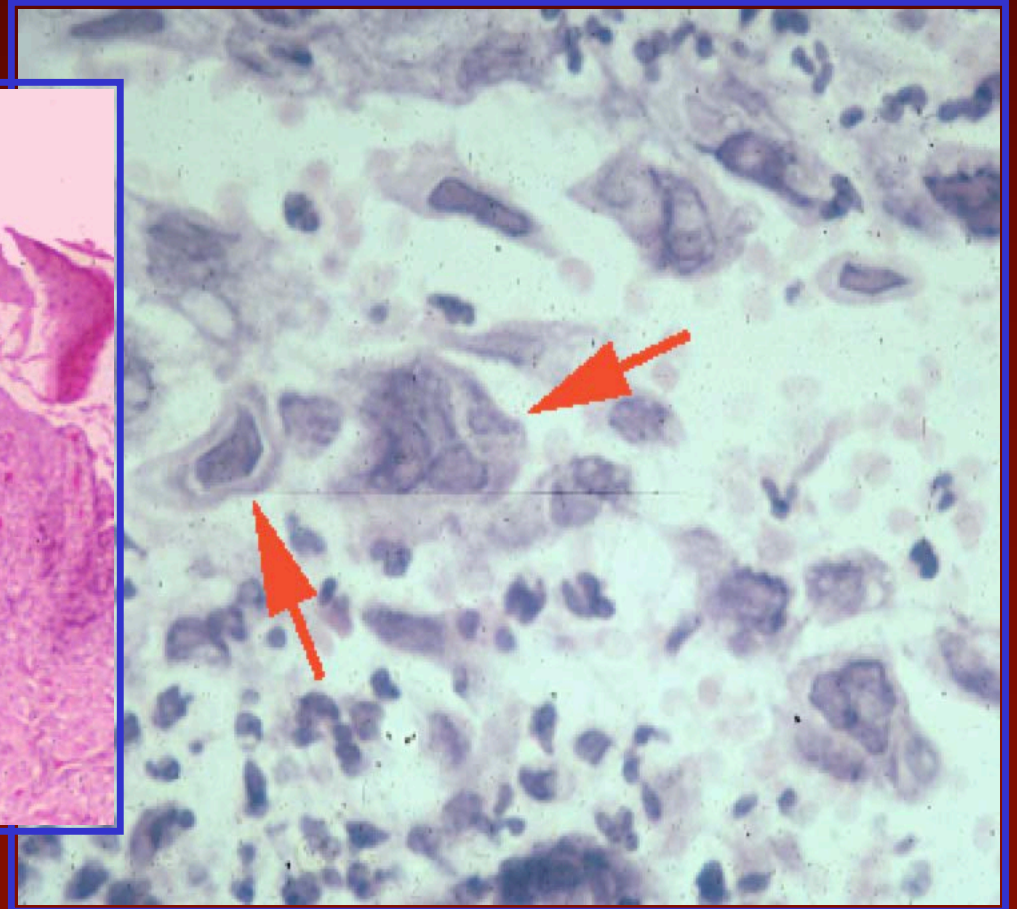
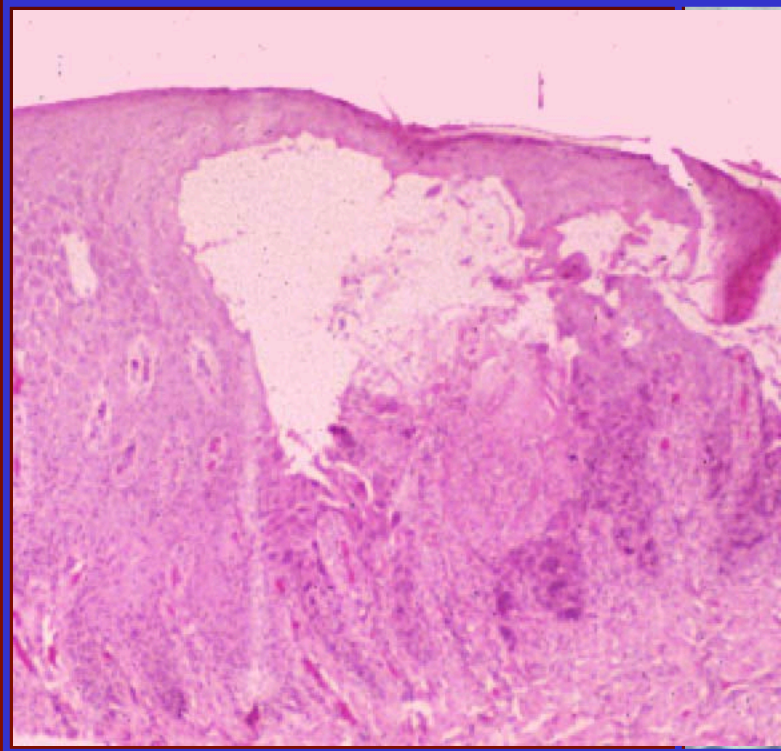


Primary Herpetic Gingivostomatitis

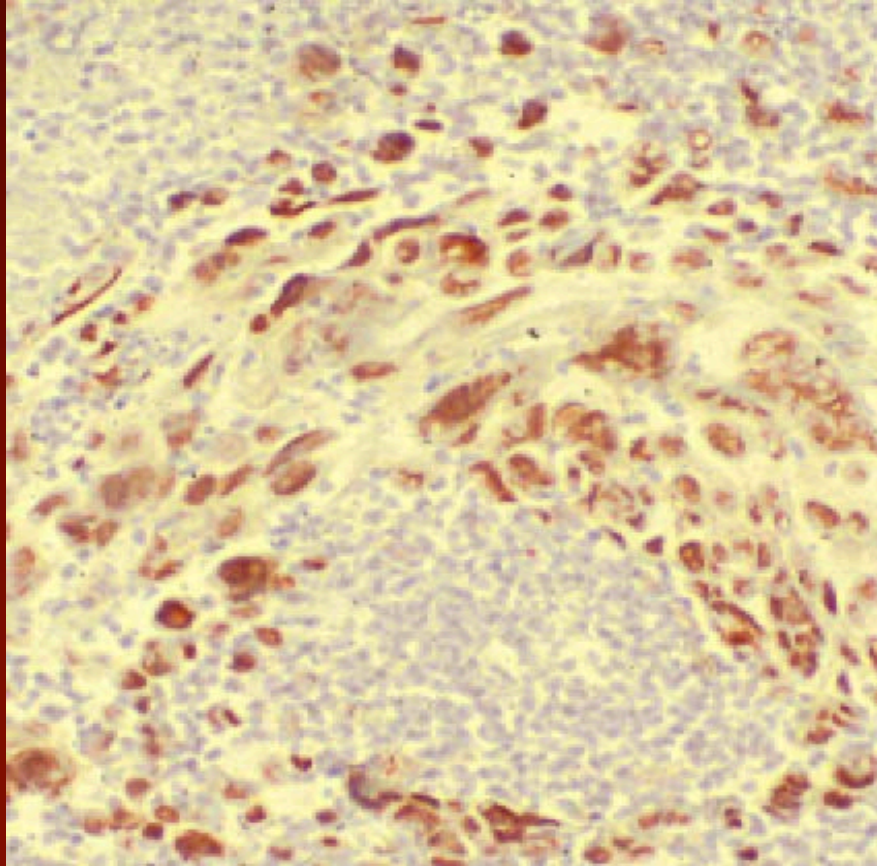


Primary Herpes Cytology

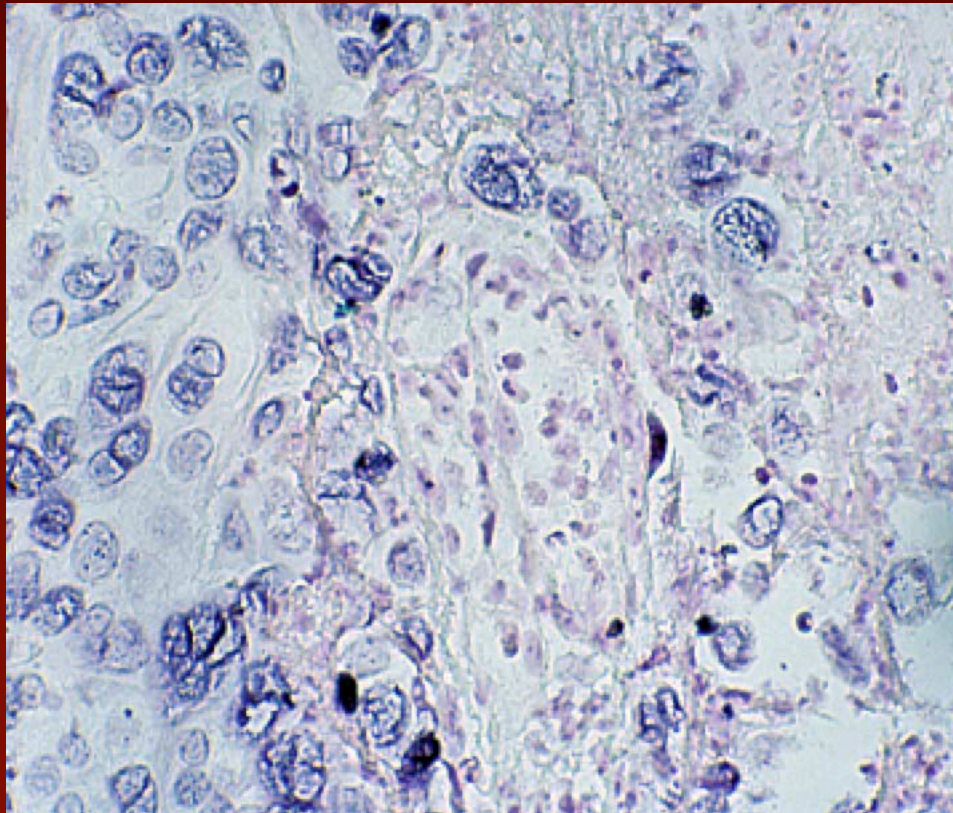
Ballooning Degeneration



Primary Herpes, Viral Antigen



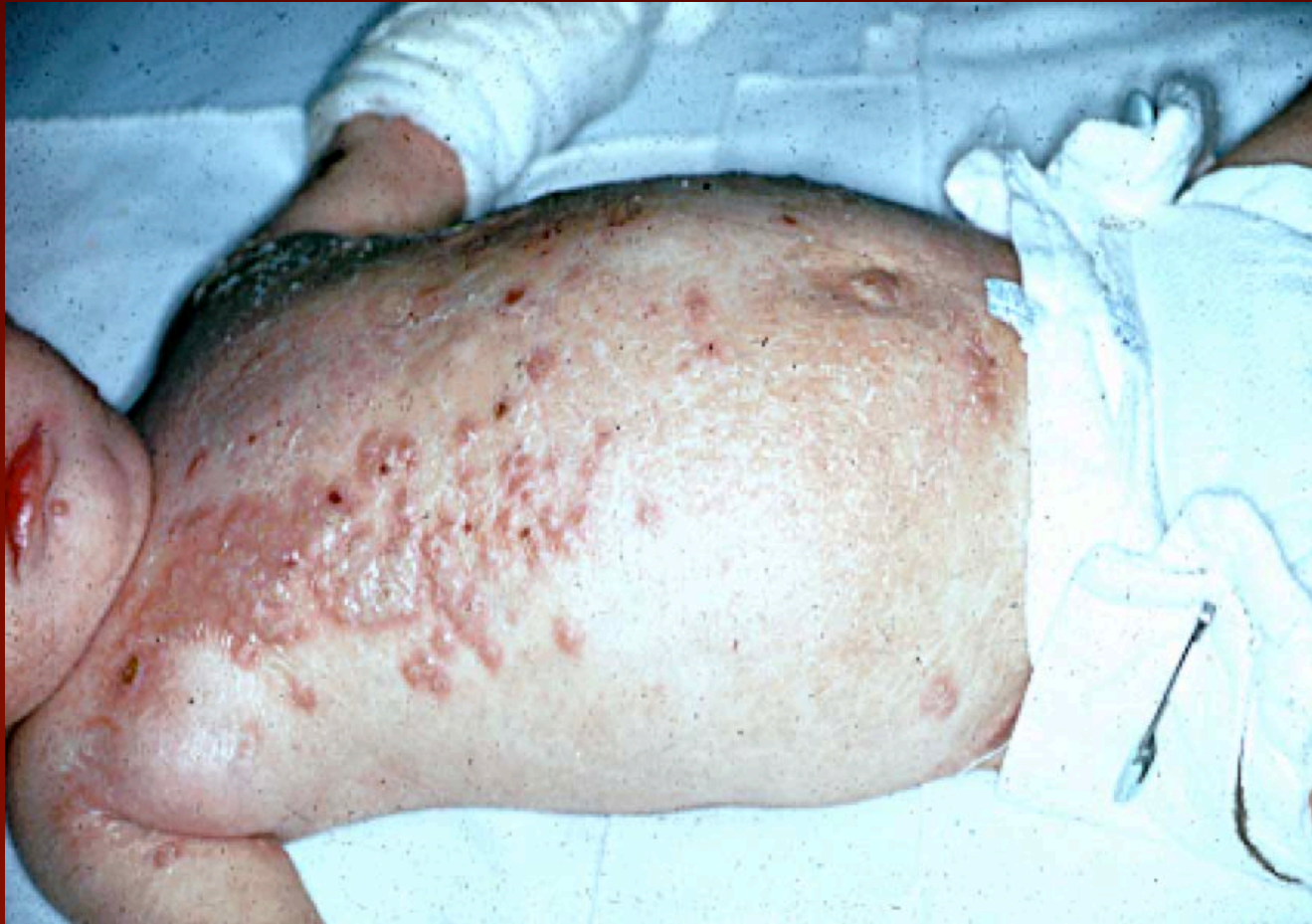Primary Herpes, Viral DNA



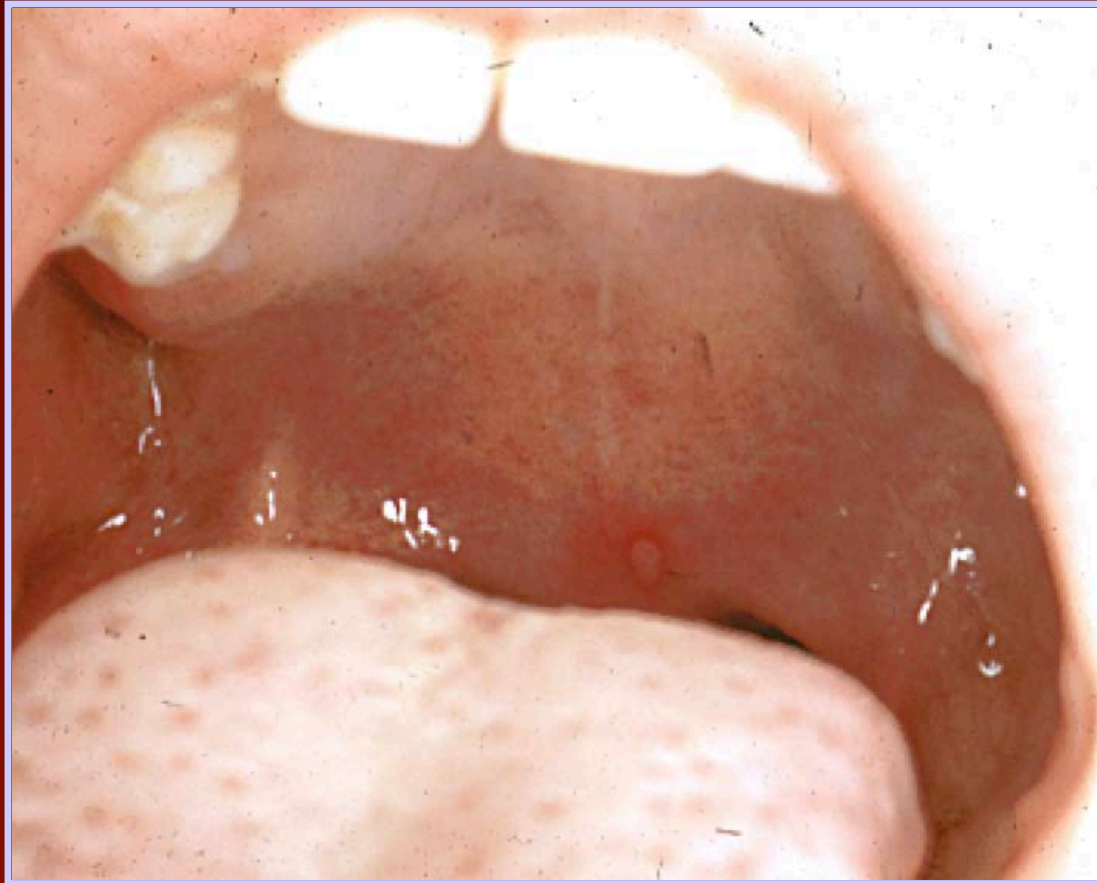Varicella Zoster

- Primary Chicken Pox
 - Cutaneous Vesicular Rash
 - Childhood Immunization
- Recurrent Shingles (Zoster)
 - Follow entire nerve distribution
 - Abrupt cessation at midline
 - May persist for three weeks
 - Recurrences
 - Post-herpetic Neuralgia,
Chronic

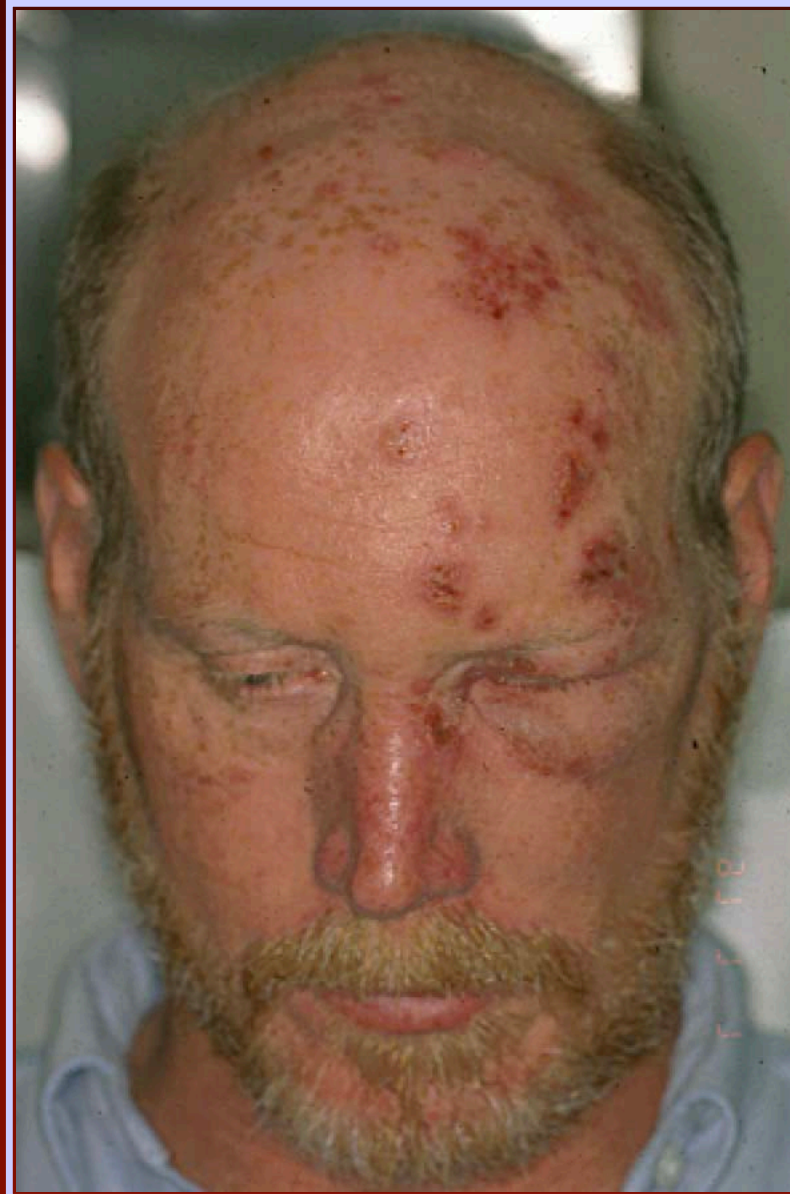Primary Varicella (Chicken Pox)



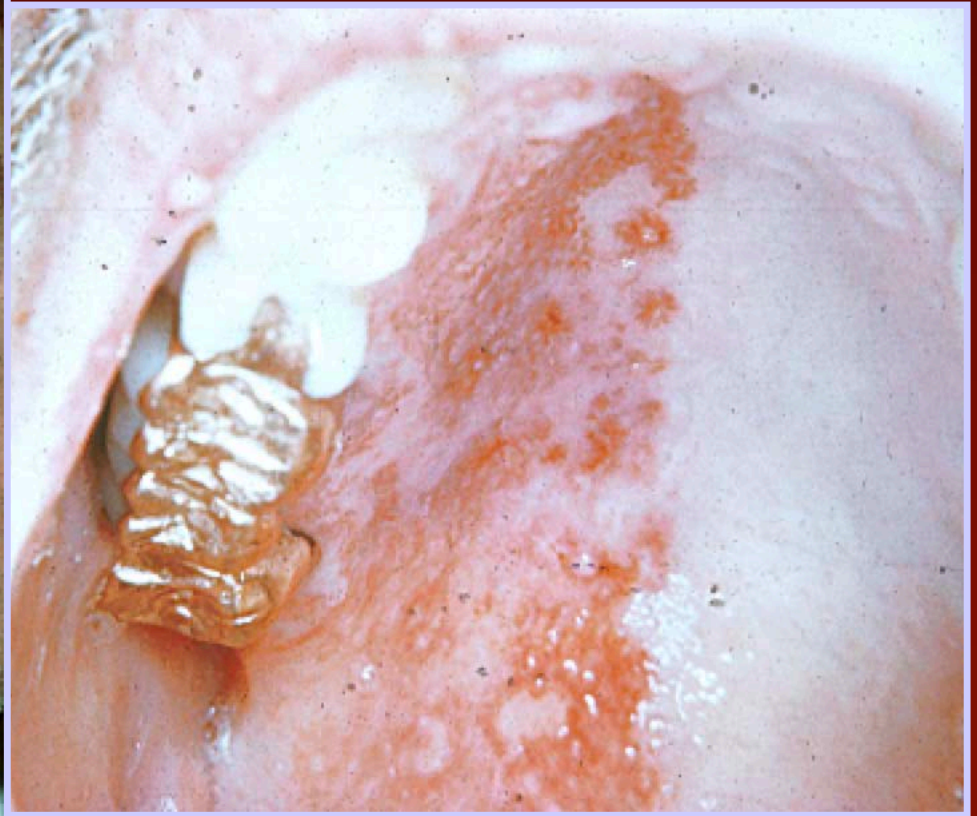
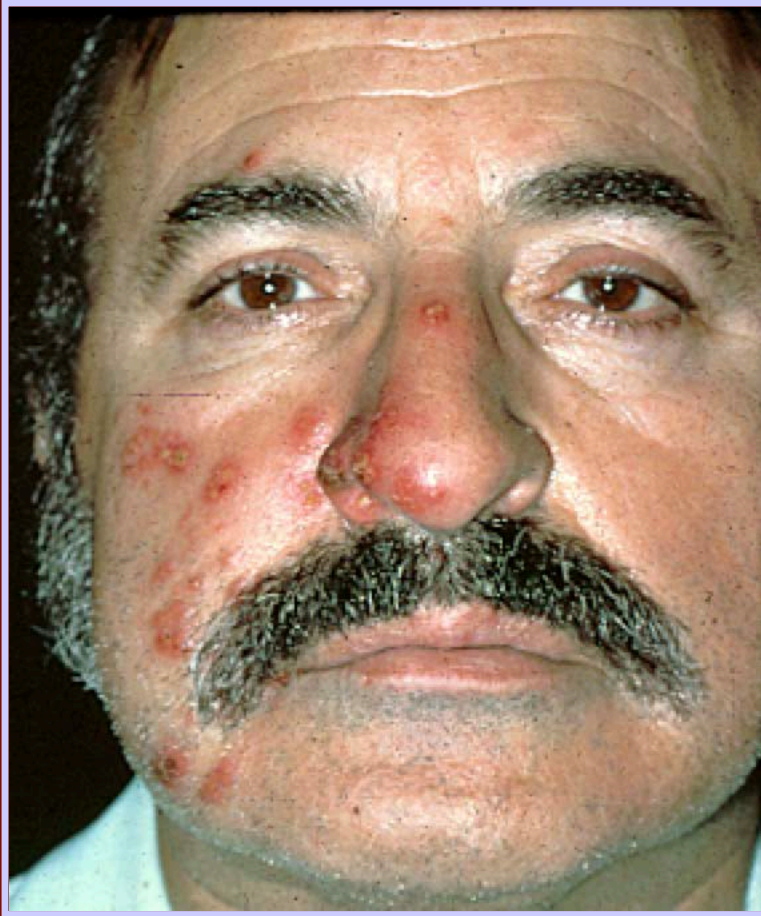
Primary Varicella (Chicken Pox)



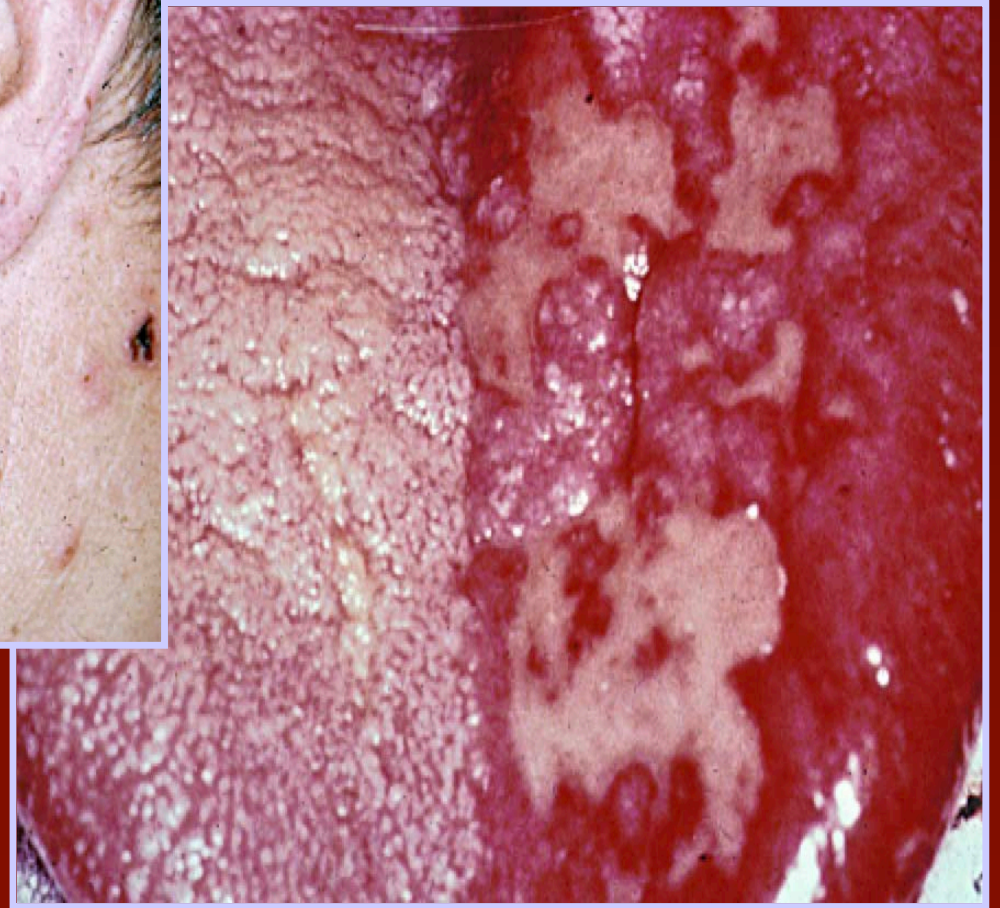
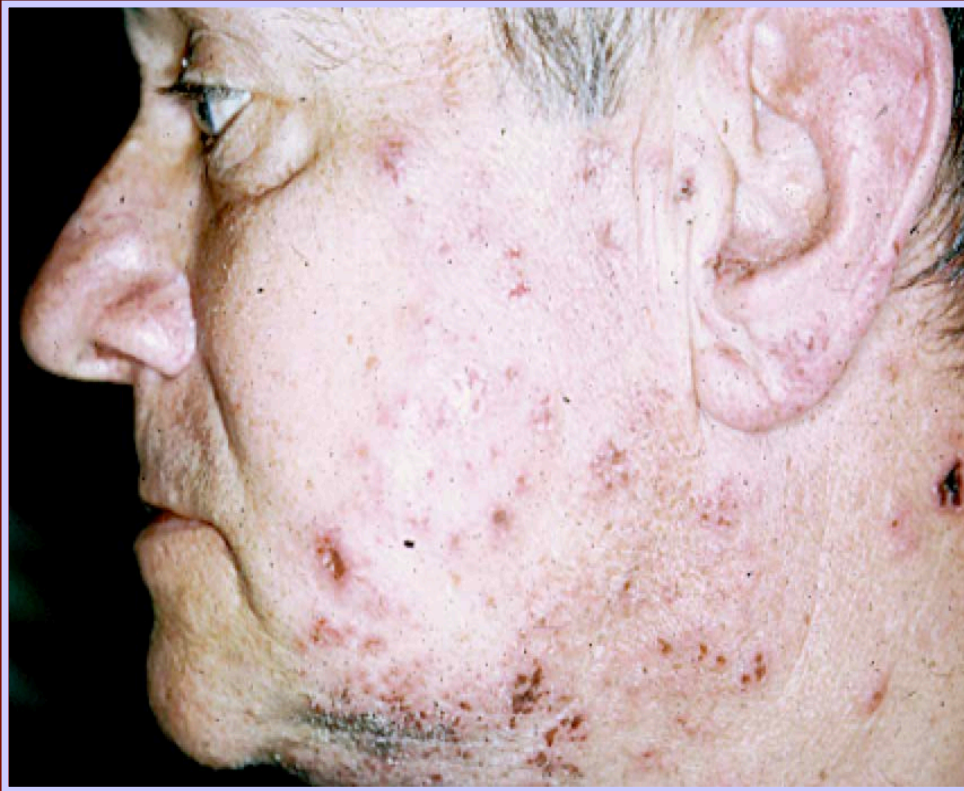Zoster, Ophthalmic Division



Zoster, Maxillary Division



Zoster, Mandibular Division



Enteroviruses

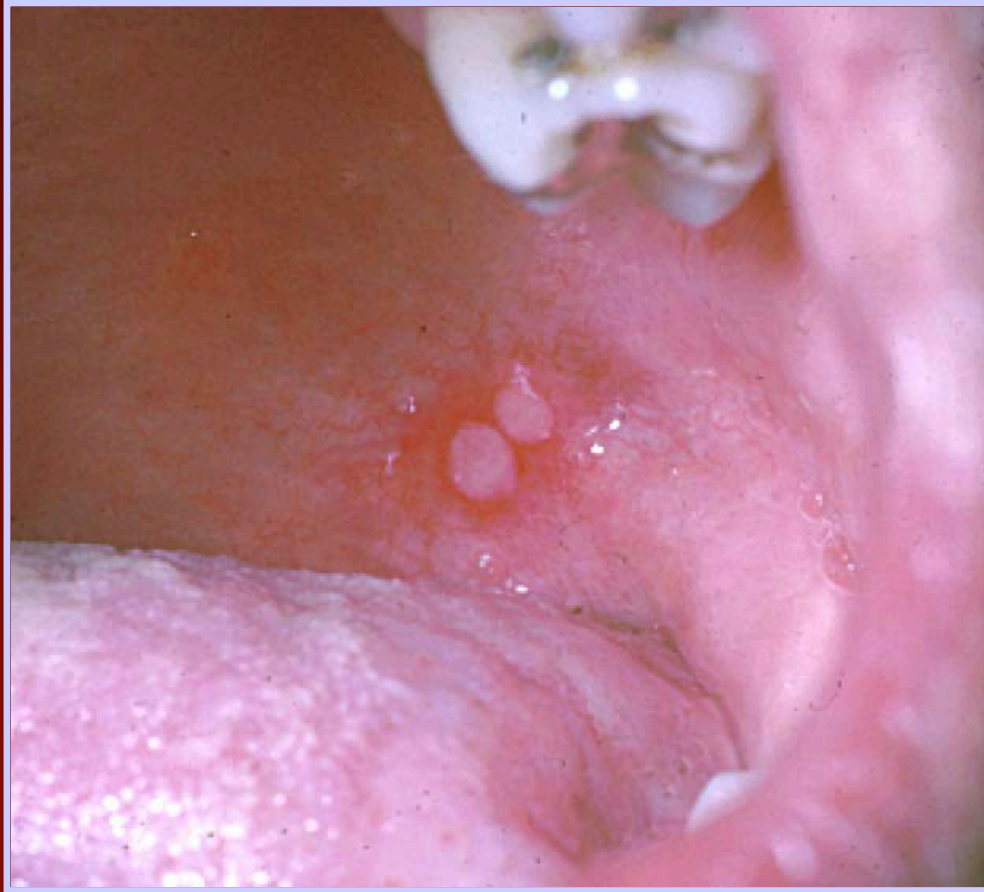
- Include ECHO and Coxsackies
- No latency
- Numbered genotypes and serotypes
- Fever, Malaise and Diarrhea
- Typing by Stool Culture
- Paliative Treatment, 10 day course
- Foor oral vesicular syndromes
 - Nonspecific enterovirus vesicular stomatitis
 - Herpangina
 - Hand Foot and Mouth Disease
 - Acute Lymphonodular Pharyngitis

The Enteroviruses

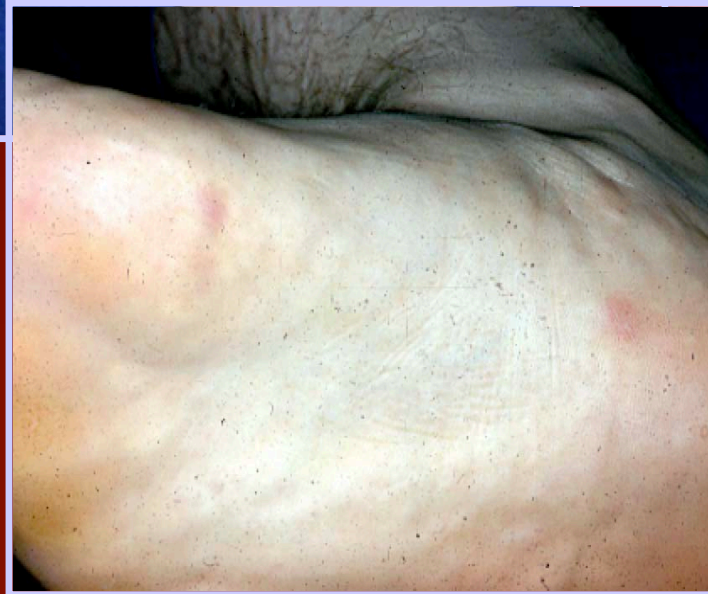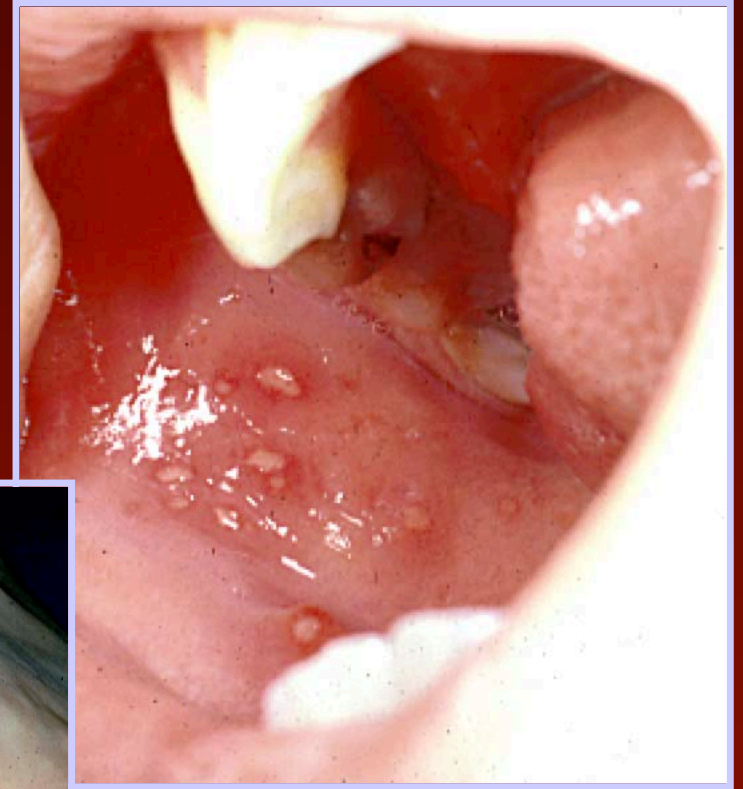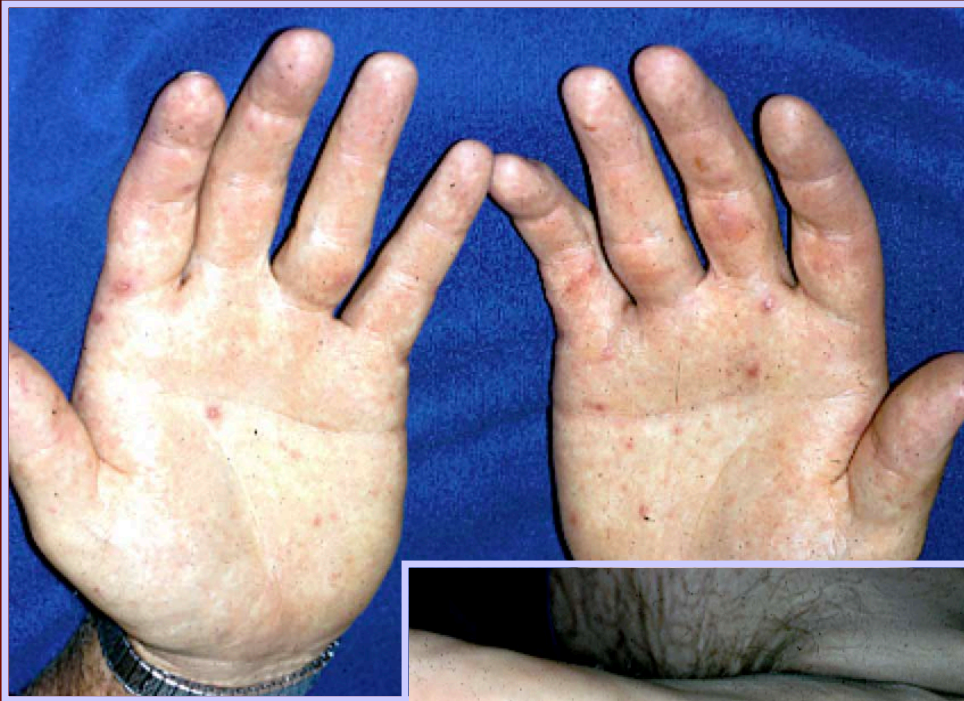ENTEROVIRUSES AND DISEASES OF THE HEAD AND NECK

DISEASE	COX A	COX B	ECHO/ENTERO
HERPANGINA	1-10, 16, 22	1-5	6, 9, 11, 16, 17, 22, 25
LYMPHONODULAR PHARYNGITIS	10		
MISC STOMATITIS	5, 9, 10, 16	2, 5	9, 1, 20
HAND FOOT & MOUTH	16		

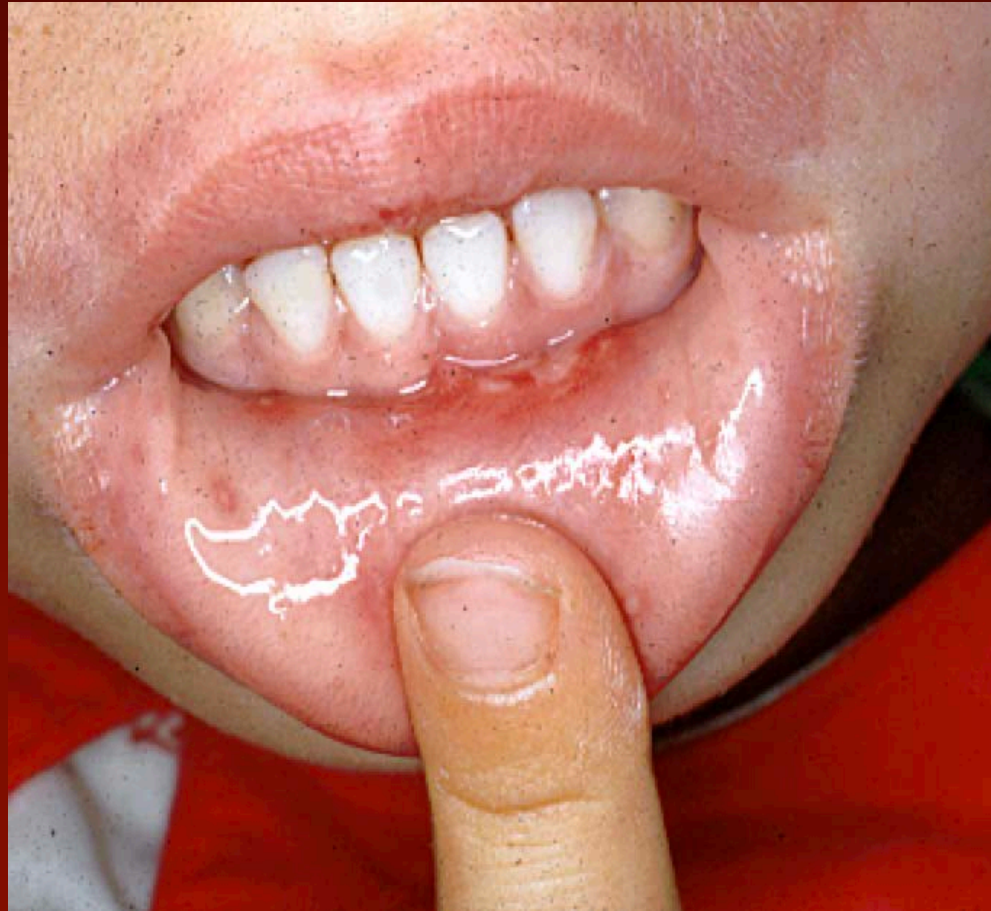Enterovirus Stomatitis



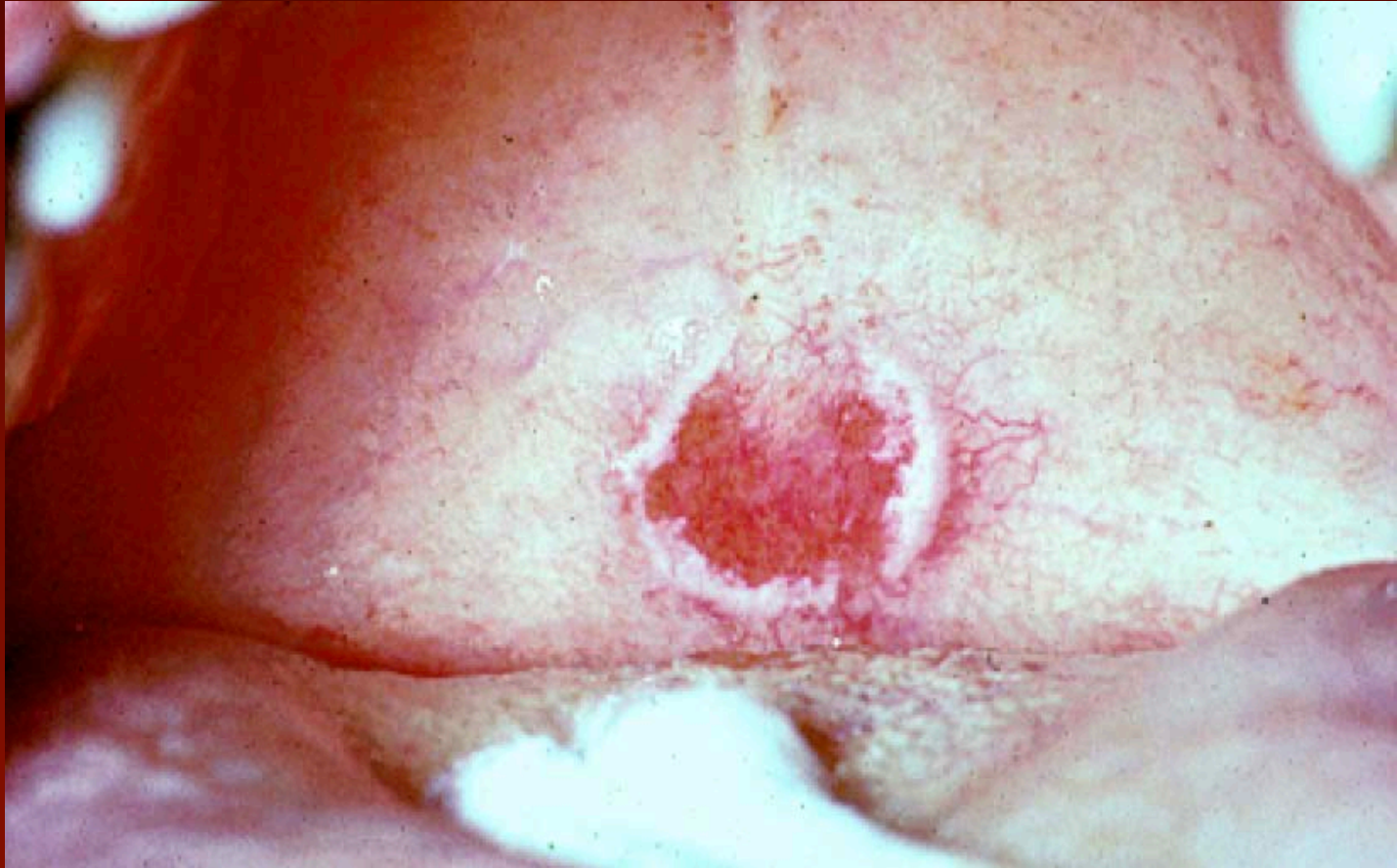Hand Foot and Mouth Disease



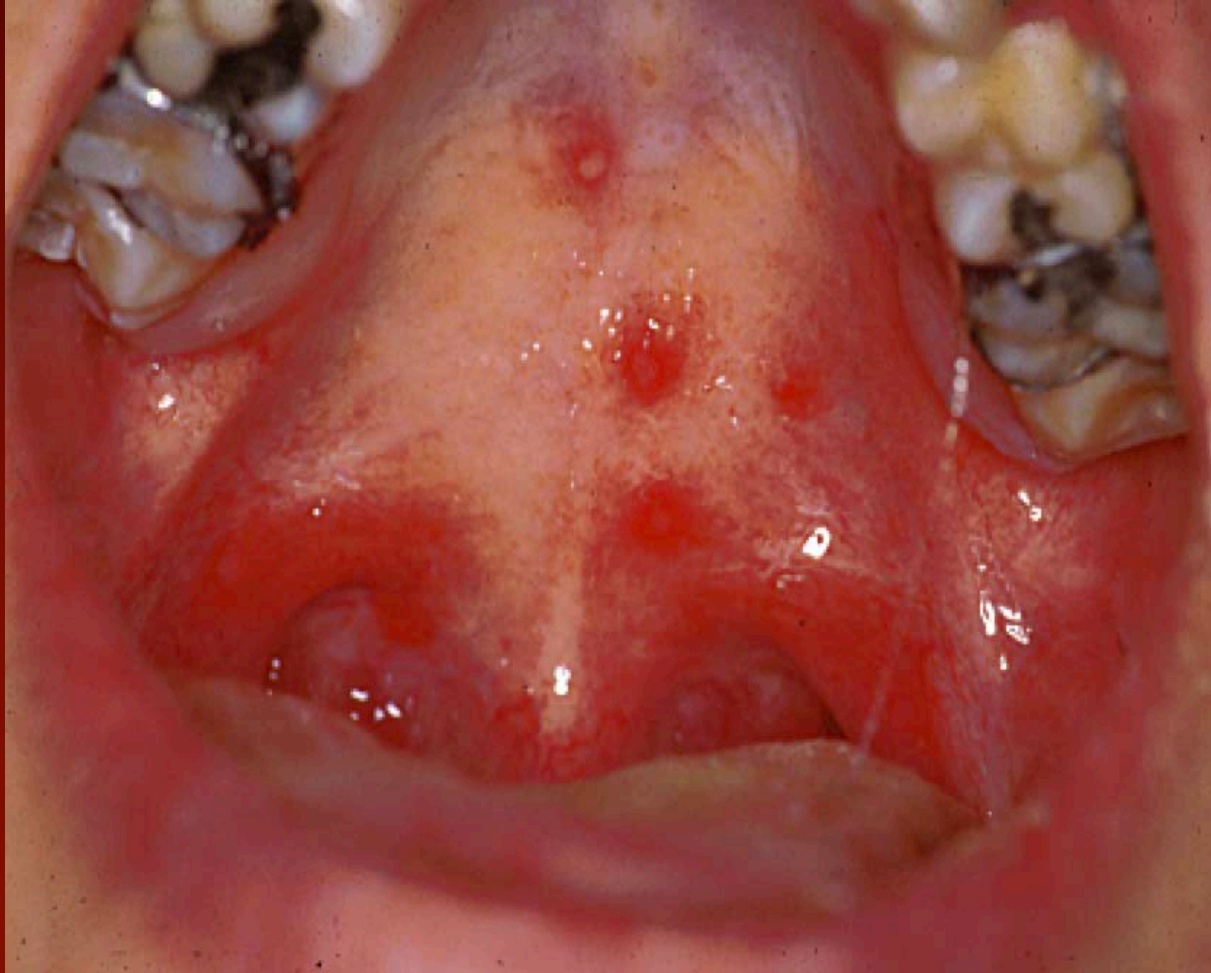Hand Foot and Mouth Disease



Herpangina



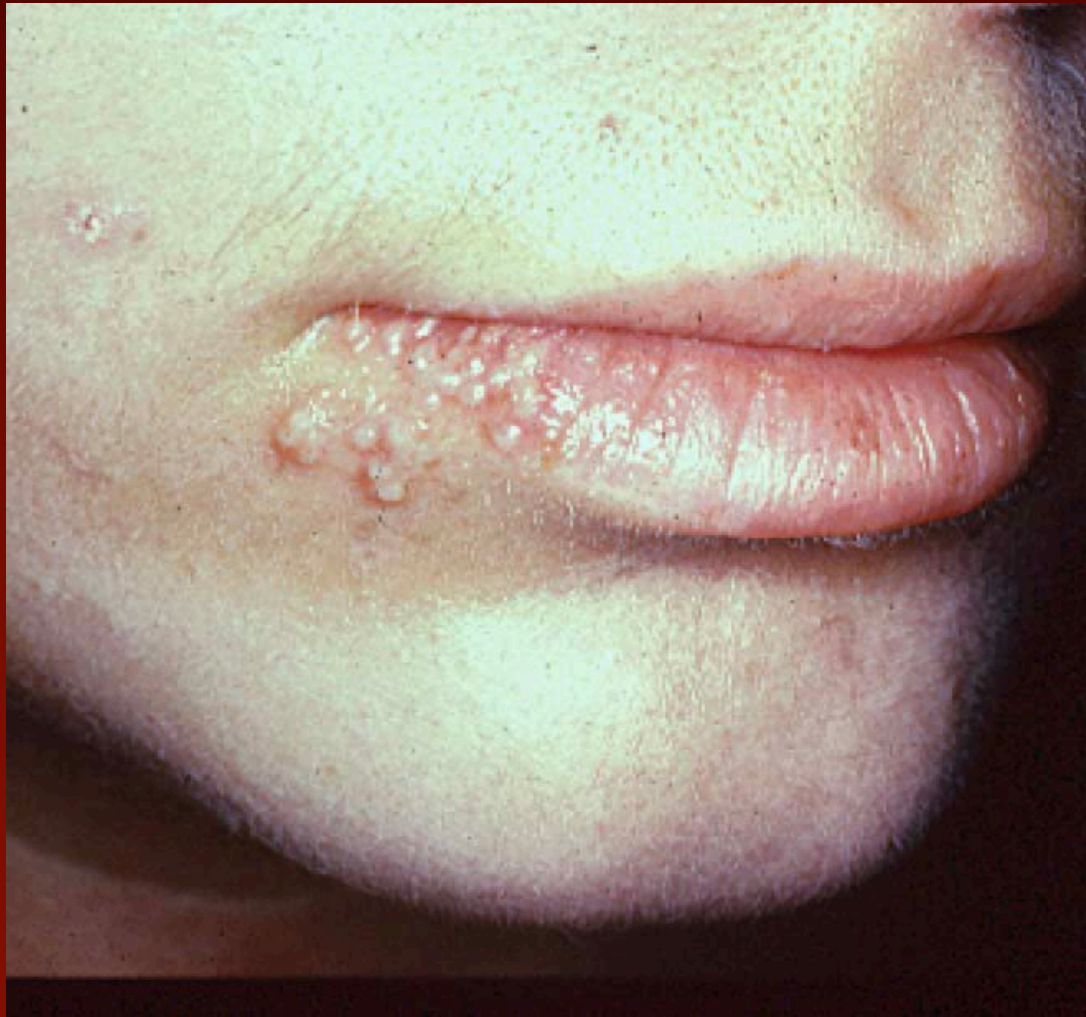Herpangina



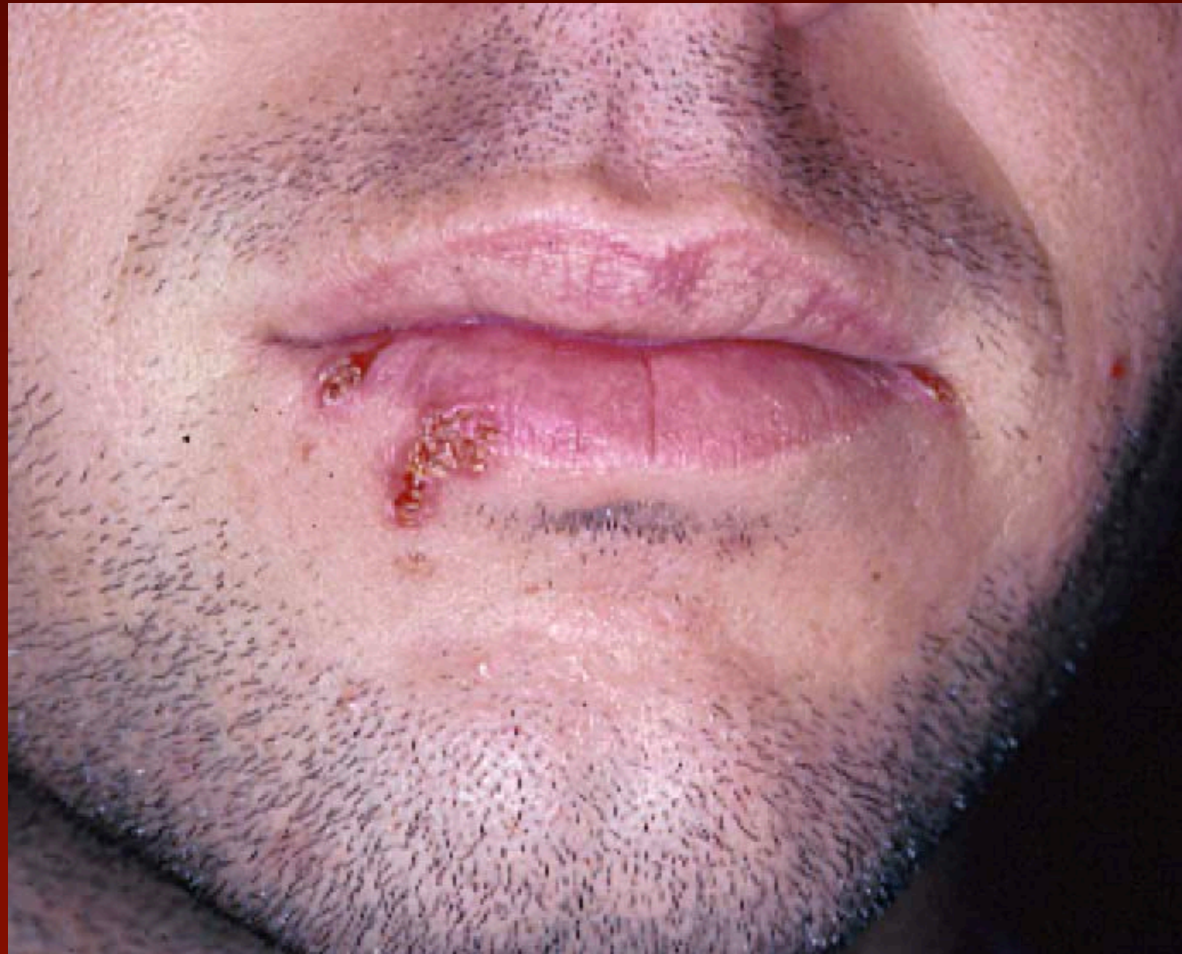NonFebrile Associated Vesicles

- Herpes Labialis
- Intraoral Recurrent Herpes
- Allergic Stomatitis

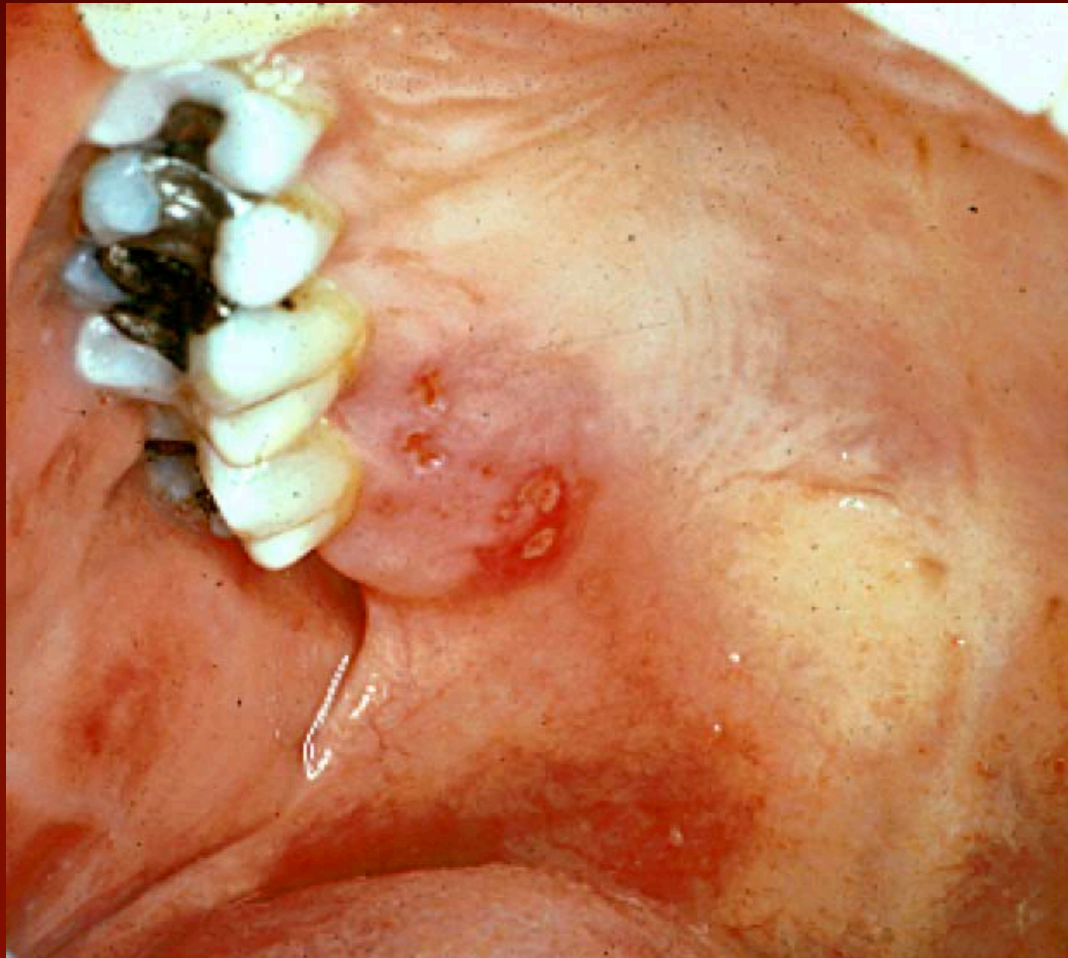
Herpes Labialis



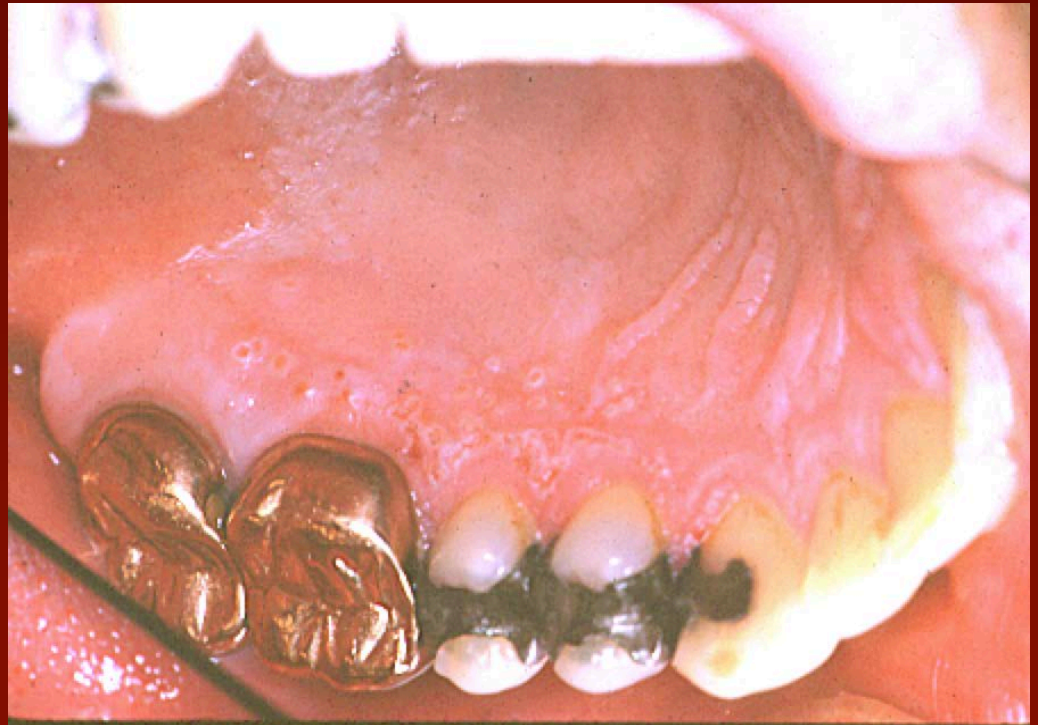
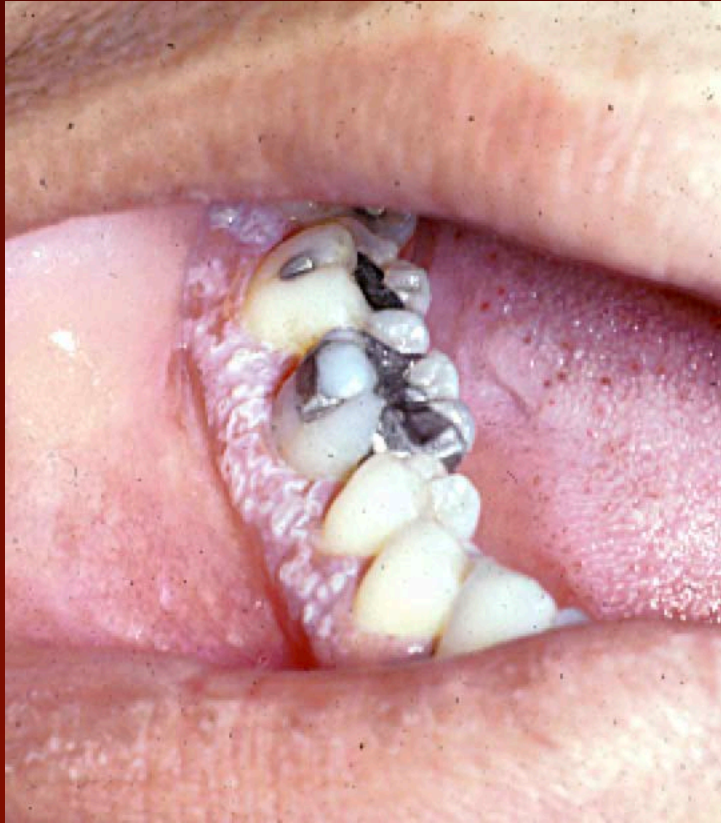Herpes Labialis, Crust



Recurrent Intraoral Herpes



Recurrent Intraoral Herpes



Treatment for HSV and VZV

HSV Active Disease

- Infectious for 5 days
- Topicals not effective
- Systemic effective
only if given first day
of infection

VZV Active Disease

- Systemic Antivirals

Prophylaxis

- Systemic
administration
- Rx prior to
precipitating events
- Continue 7-10 days

HSV, VZV Therapy

- Acyclovir
- Side groups
 - Alter Bioavailability
 - Alter Half Life
- Topicals
- Oral Systemic

Therapy

Antivirals - Herpes group viruses

Acyclovir (Zovirax)

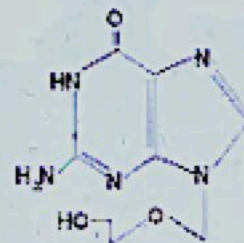
Valacyclovir (Valtrex)

Penciclovir (Denavir)

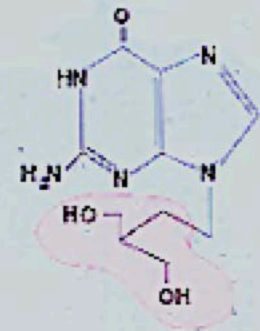
Famciclovir (Famvir)

Foscarnet

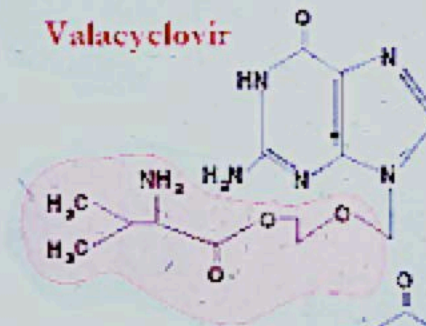
Acyclovir



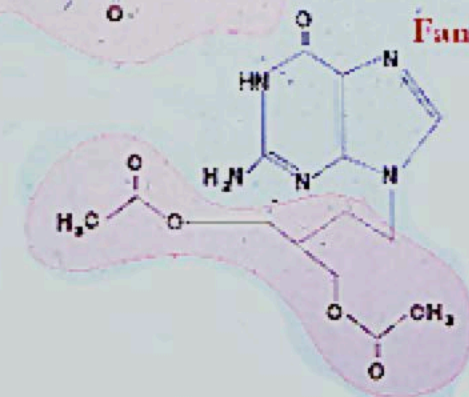
Penciclovir



Valacyclovir



Famciclovir



Therapy

ACYCLOVIR

DNA chain arrest
Oral Bioavailability - 20%
Half-life: 1-2 hours

PENCICLOVIR

DNA chain arrest
Oral Bioavailability - 0%*
Half-life: 1-2 hours

*topical only

FAMCICLOVIR

DNA chain arrest
Oral Bioavailability - 77%
Half-life: 7-20 hours

metabolized to penciclovir

VALACYCLOVIR

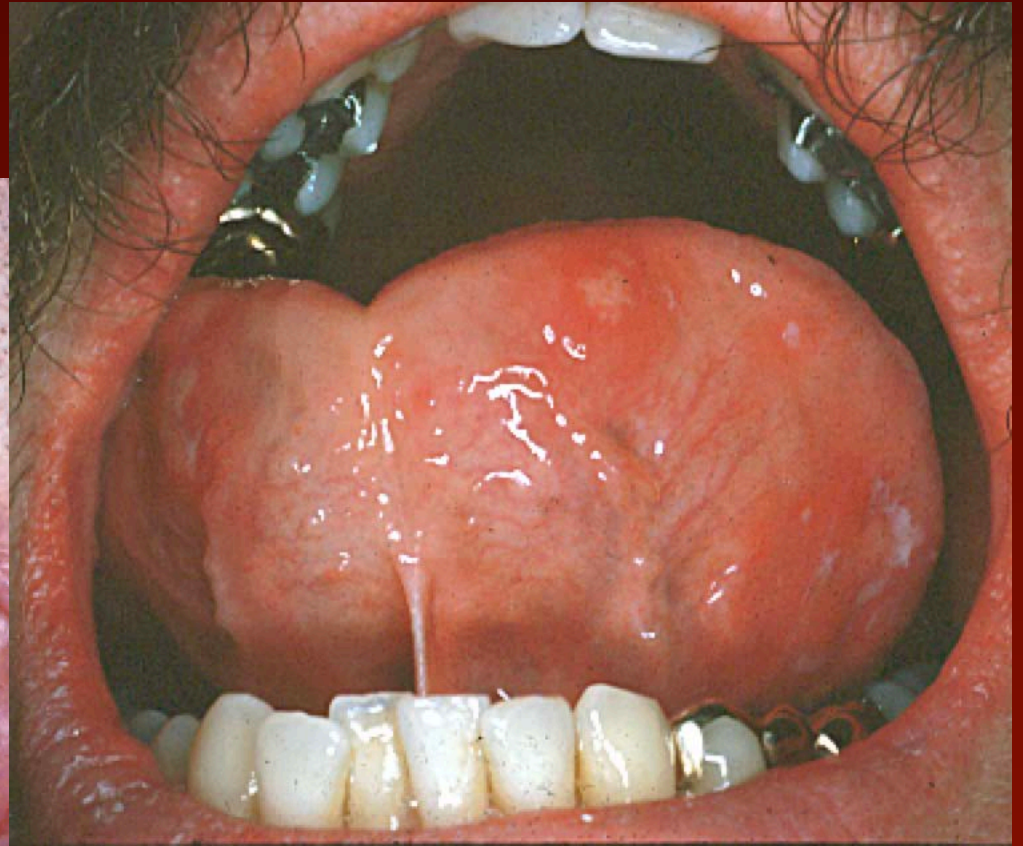
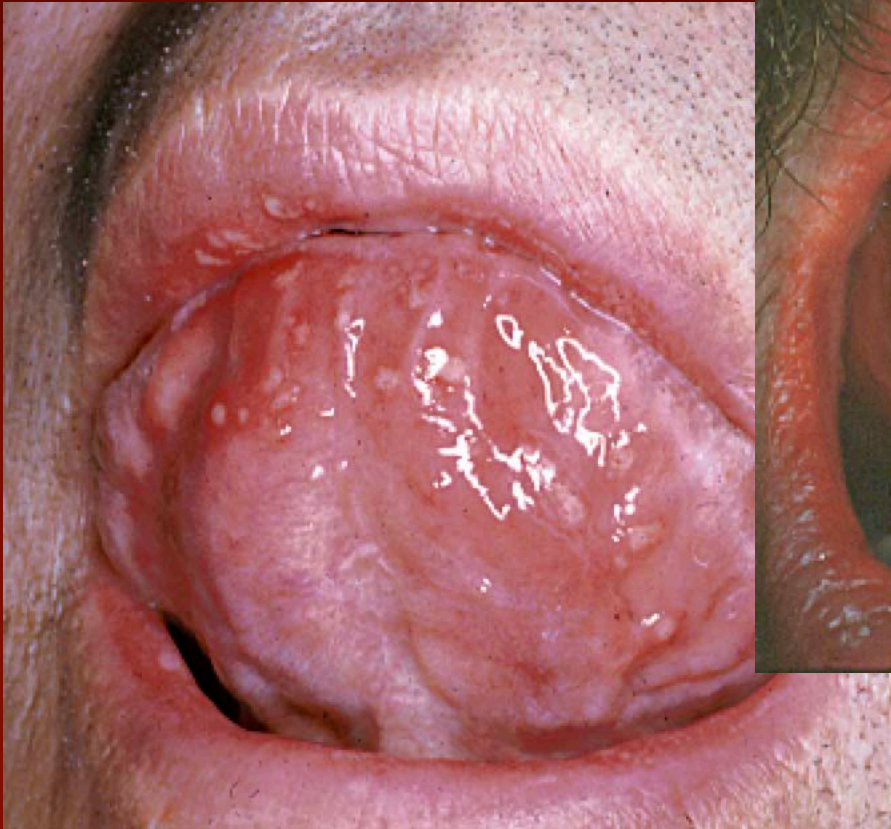DNA chain arrest
Oral Bioavailability - 55%
Half-life: 1-2 hours

*metabolized to acyclovir

Allergic Vesicular Stomatitis

- Immediate (IgE) hypersensitivity
- Immune complex hypersensitivity
- Diffuse oral vesiculoulcerative lesions
- Afebrile
- Painful
- Antihistamine/Steroid Responsive

Allergic Stomatitis (Shell Fish)



DIAGNOSIS BY LOCATION

- Primary Herpetic Gingivostomatitis
 - Gingival, Movable mucosa
- Herpes Labialis
 - Clustered lip, ala of the nose
- Recurrent Intraoral Herpes
 - Clustered palatine, mental, long buccal
- Chicken pox
 - Diffuse over abdomen, oral
- Shingles
 - Follow entire nerve (dermatome)
- Hand Foot and Mouth Disease
 - Movable mucosa, hands, feet
- Herpangina
 - Soft Palate