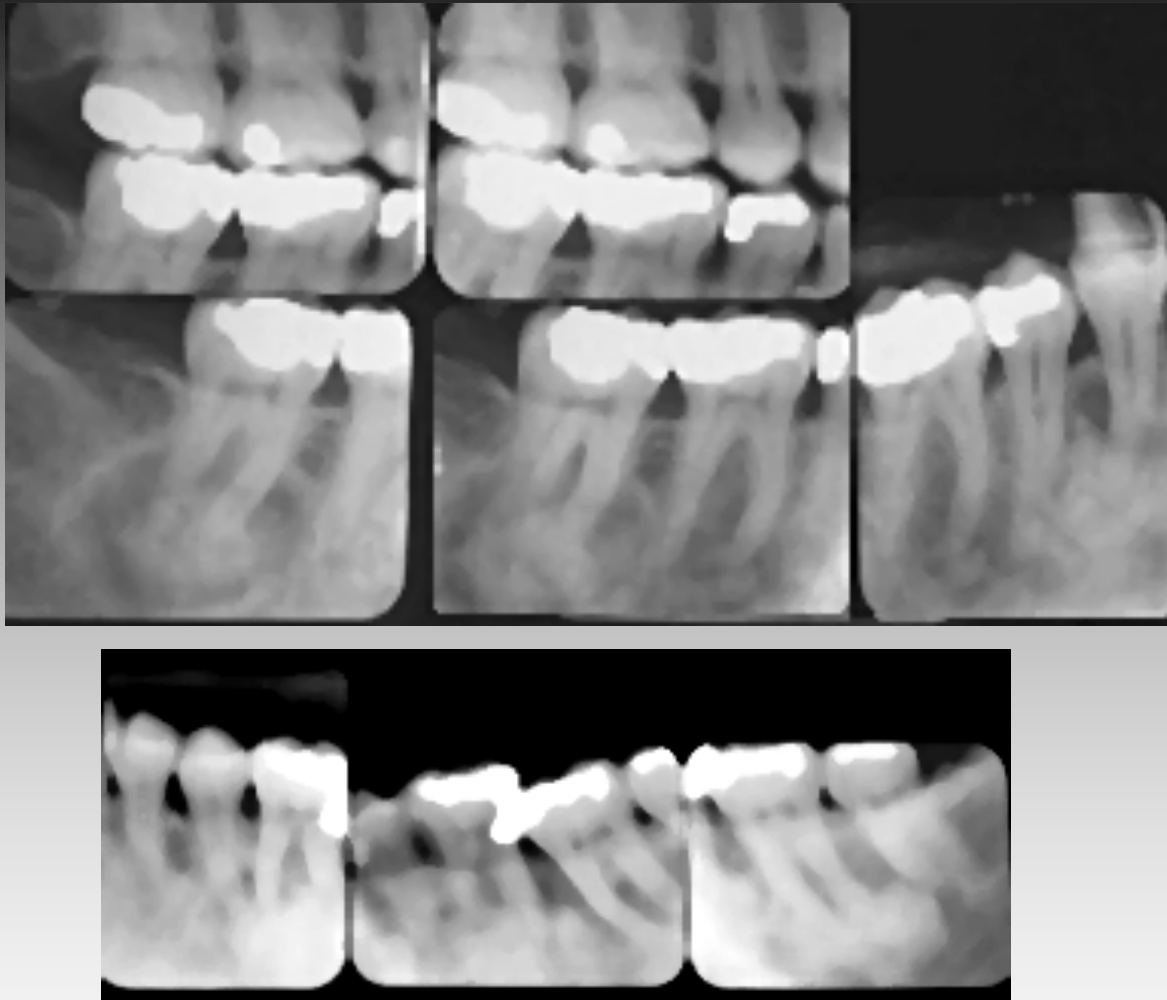


Multiple and Confluent Opacities

- Florid Osseous Dysplasia
- Osteitis Deformans
- Diffuse Sclerosing Osteomyelitis
- Torus mandibularis
- Exostoses
- Multiple osteomas (Gardner)

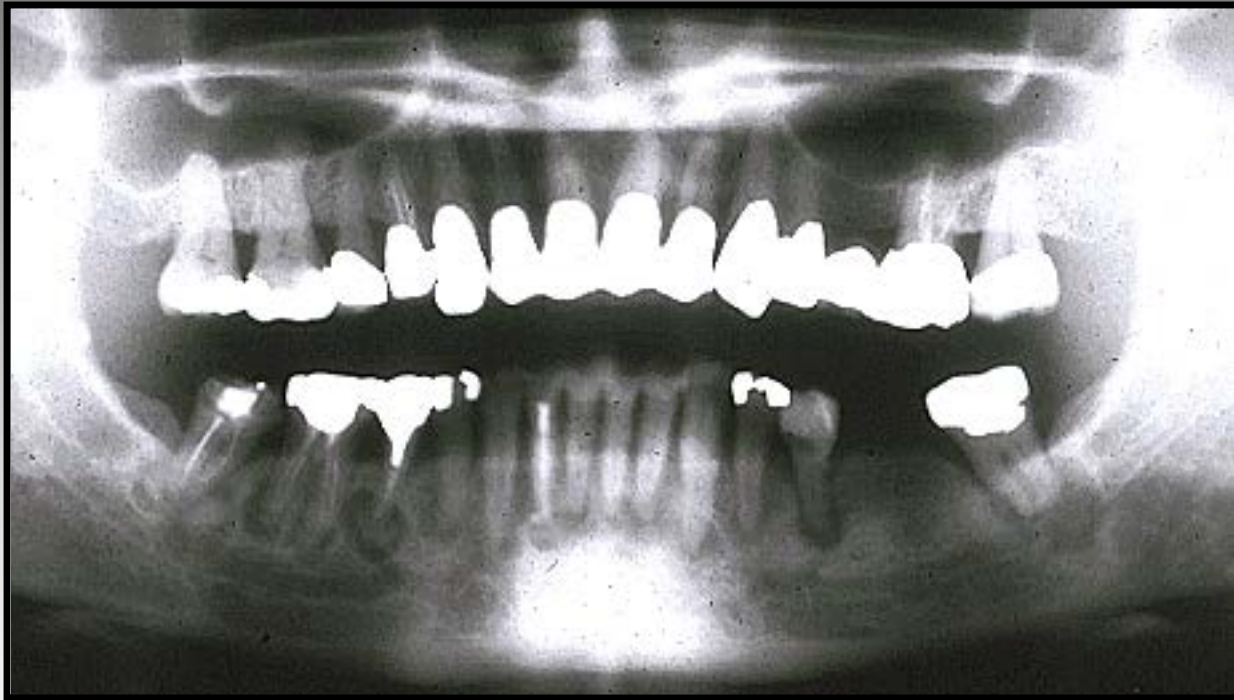Florid Osseous Dysplasia

- Black Females
- Midlife
- Multiquadrant
- Toothbearing Regions
- Nonexpansile, Asymptomatic
- Traumatic Cysts/Dense Bone
- Osteomyelitis risk



Florid Osseous Dysplasia

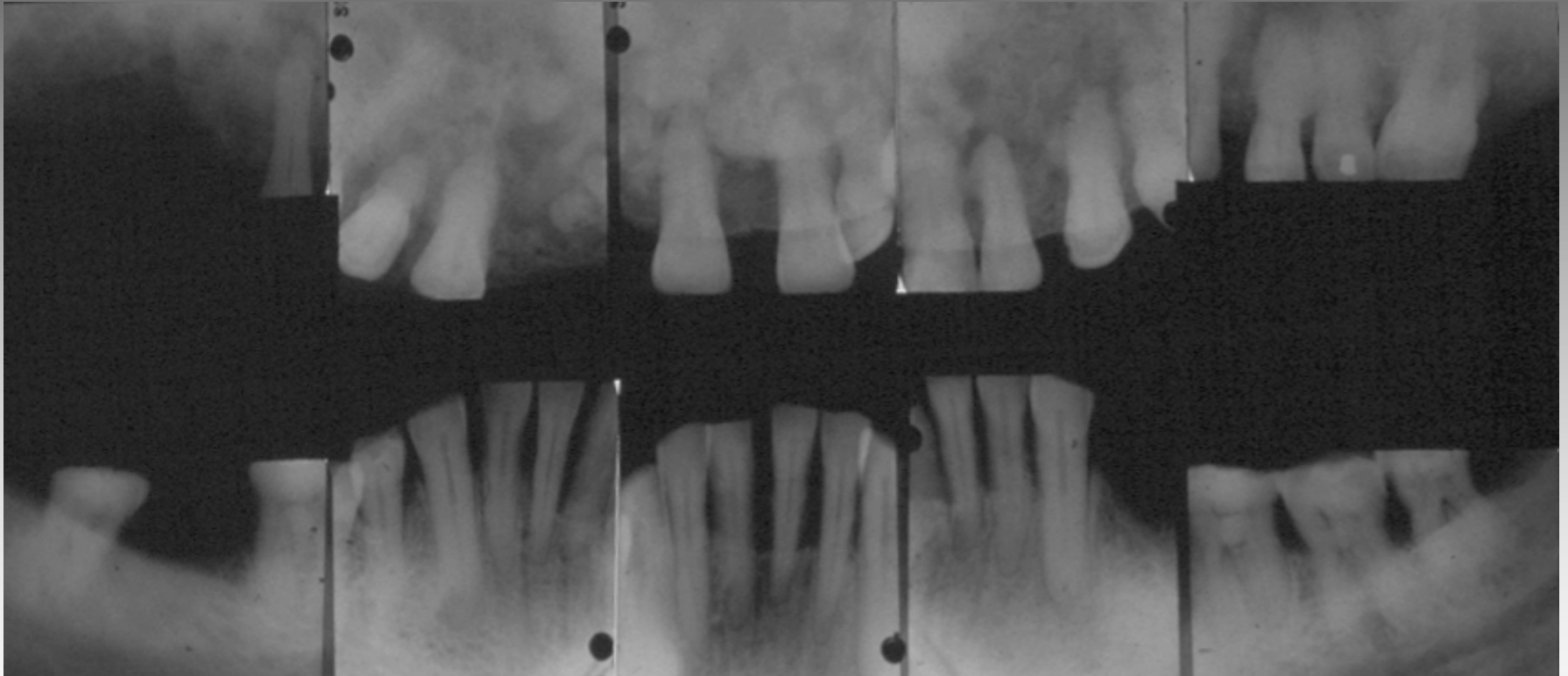
Florid Osseous Dysplasia

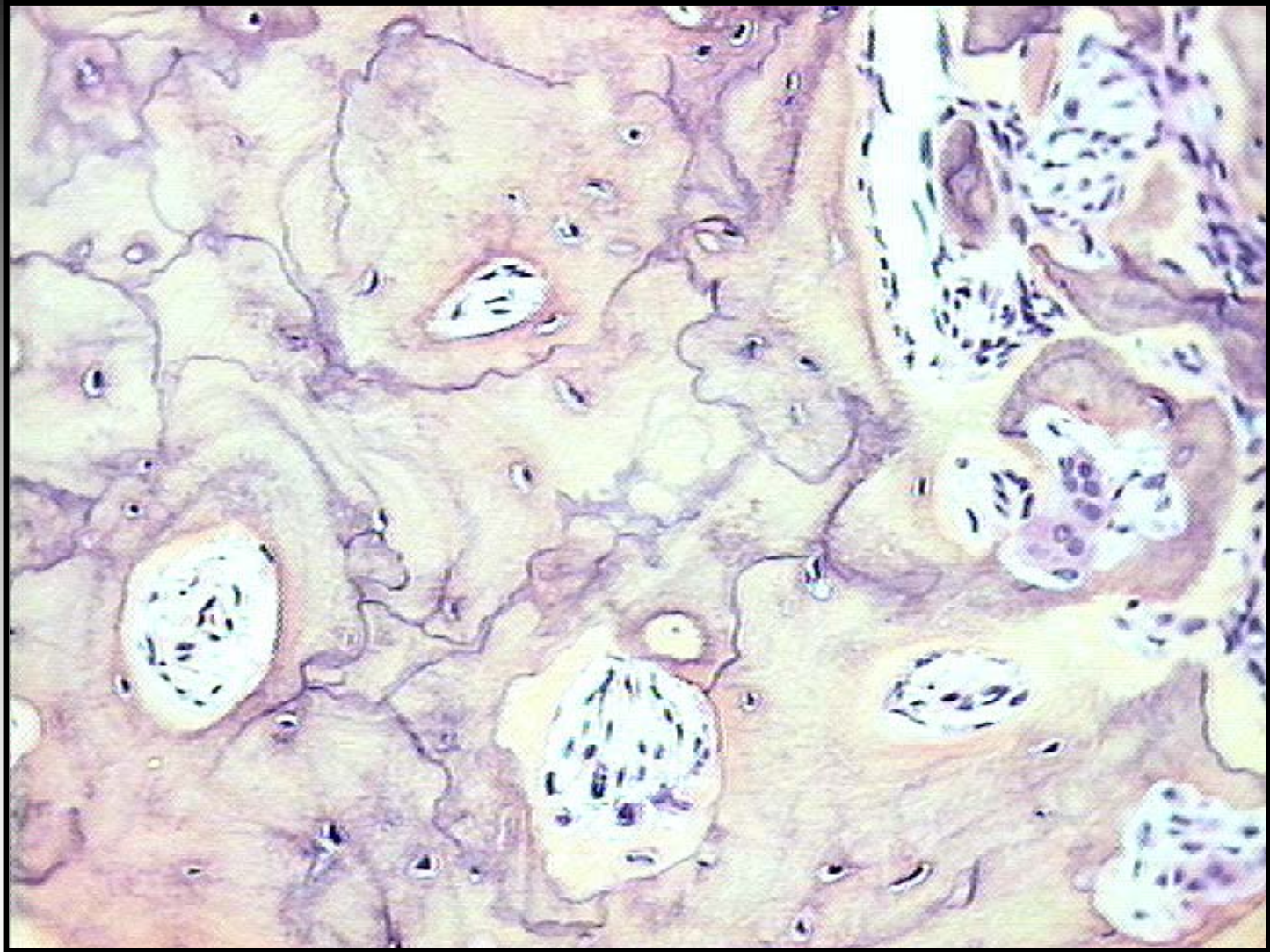


Osteitis Deformans

- Elderly
- Polyostotic
- Skull and Jaws (Cotton Wool)
 - Maxilla>Mandible
- Cranial Nerve Deficits
- Mosaic Bone
- Alkaline Phosphatase
- Normal Calcium, Phosphorus
- Giant Cell Lesions, Sarcomas

Osteitis Deformans (Paget's)

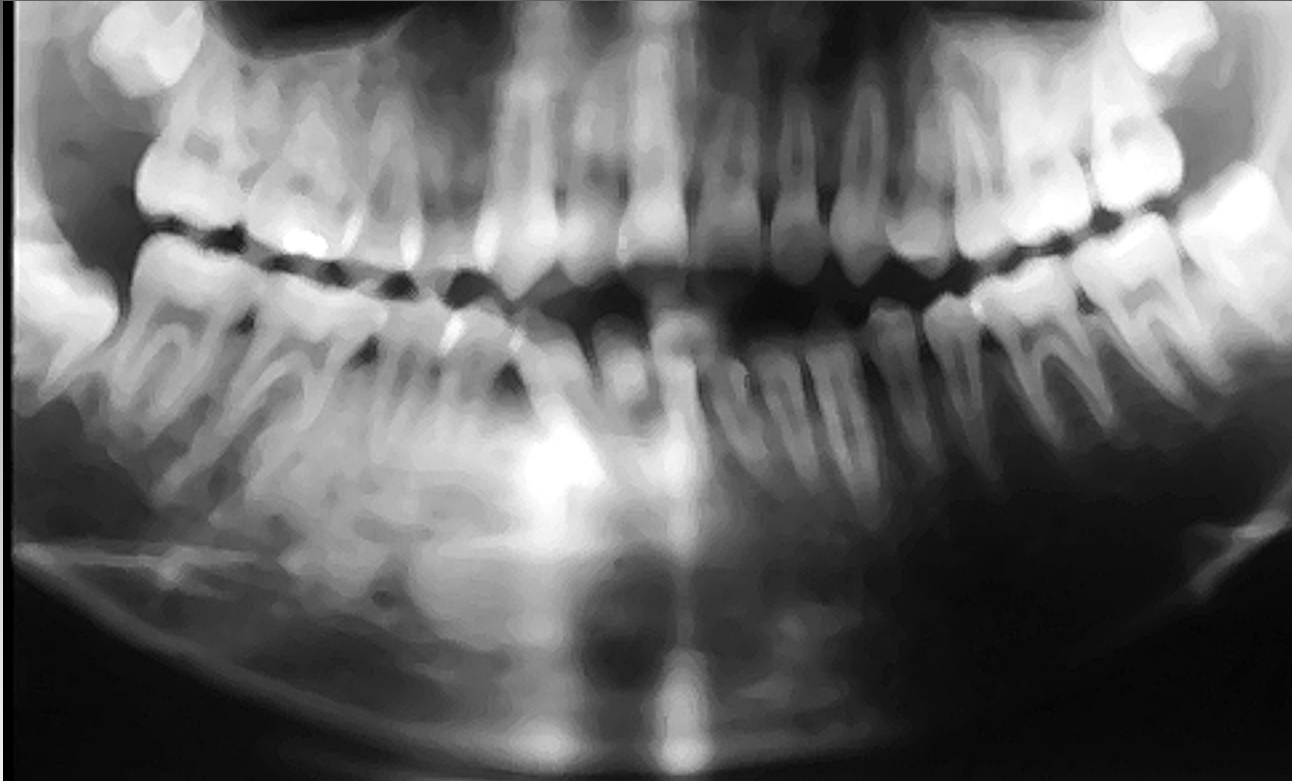




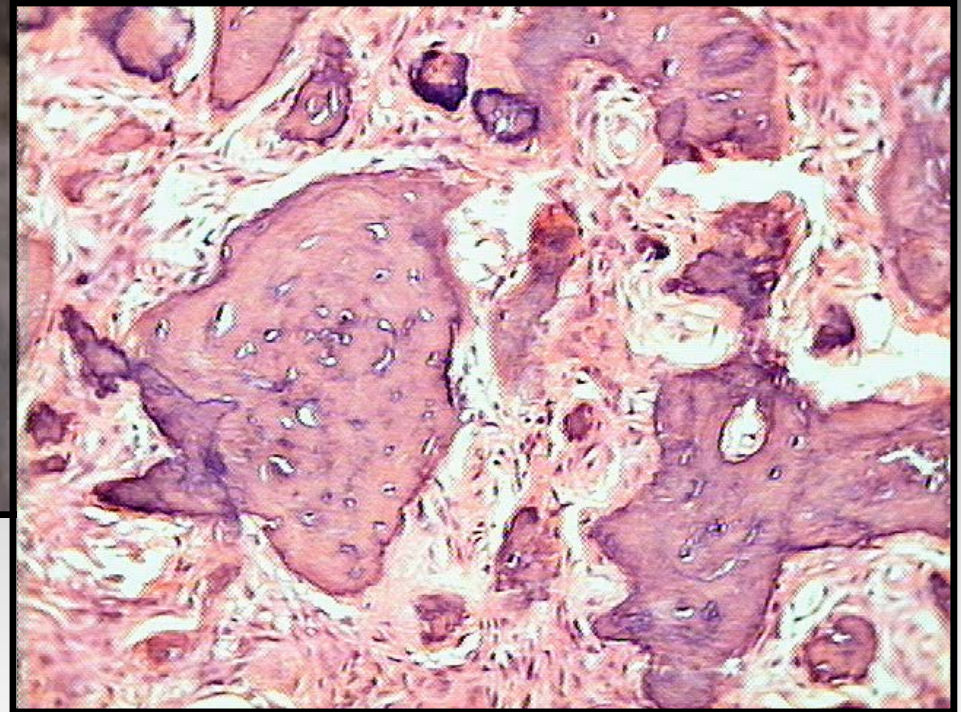
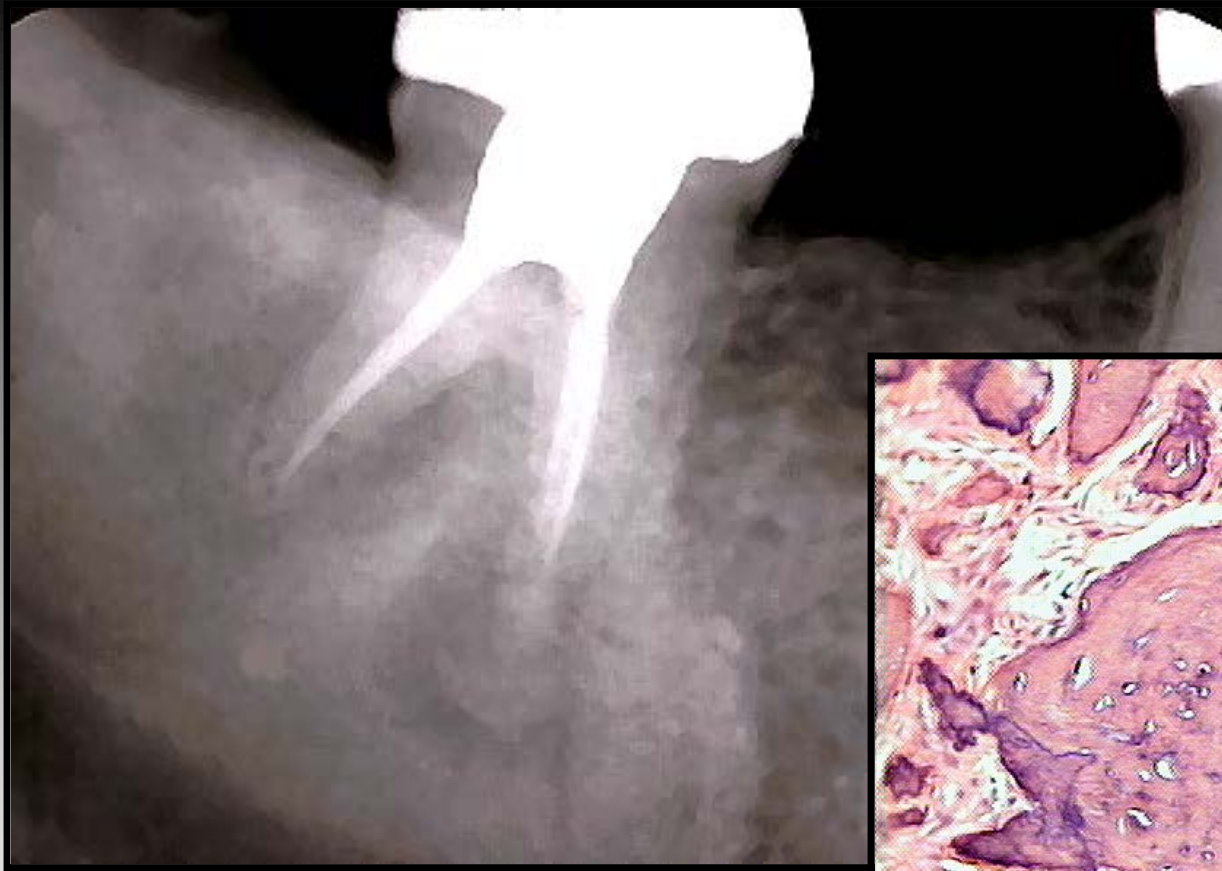
Mosaic bone (Paget's)

Chronic Sclerosing Osteomyelitis

- Childhood, Teens
- Episodic low grade pain
- Single Quadrant
- Infectious Source
 - Anaerobic bacteria
 - Odontogenic ?
- Expansile, Ill-defined
- Culture and Sensitivity
- Long Course Antibiotics



Diffuse Sclerosing Osteomyelitis

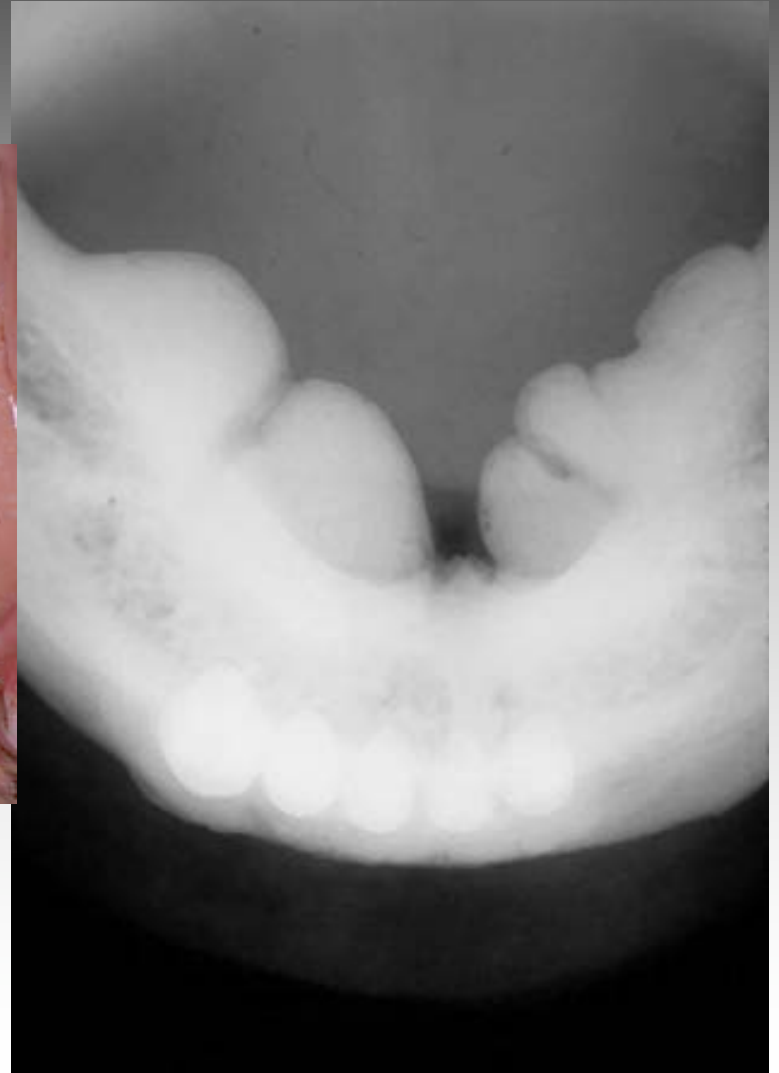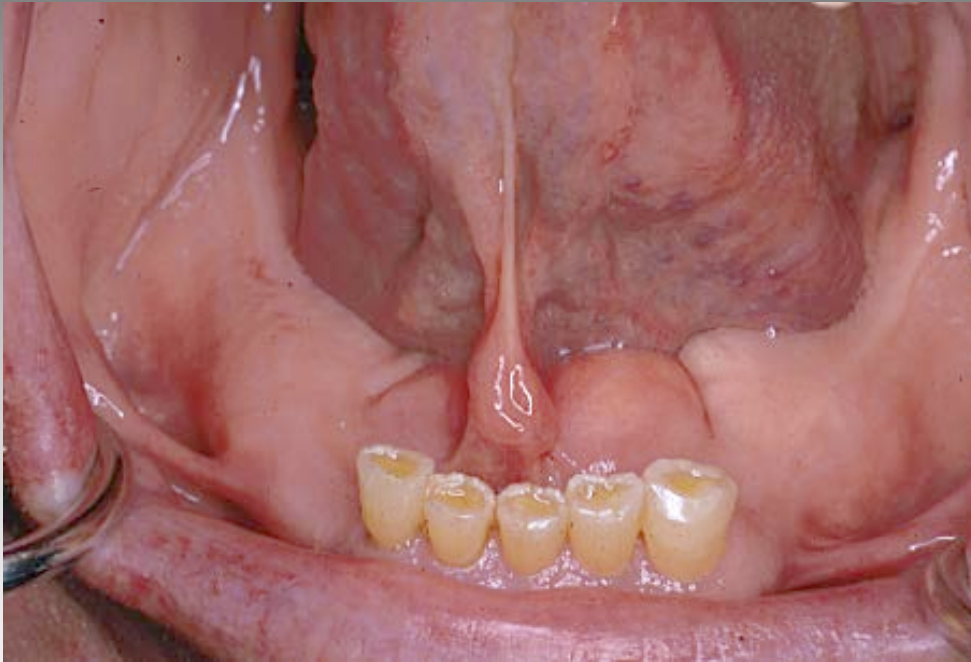


Diffuse Sclerosing Osteomyelitis

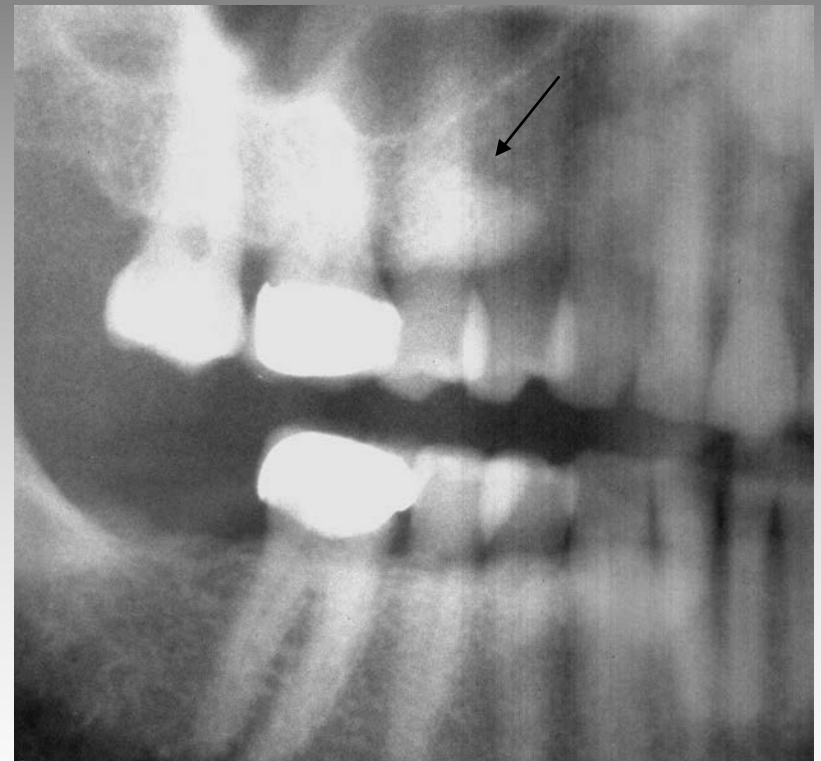
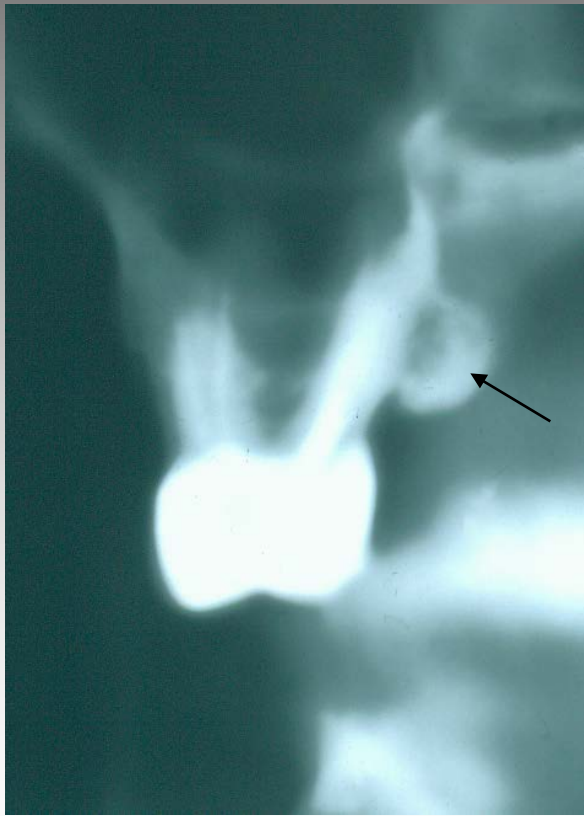
Exostoses and Tori

- Adults
- Slow progressive growth
- Growth cessation
- Clinically evident masses
- Premolar/Molar Regions

Mandibular Tori



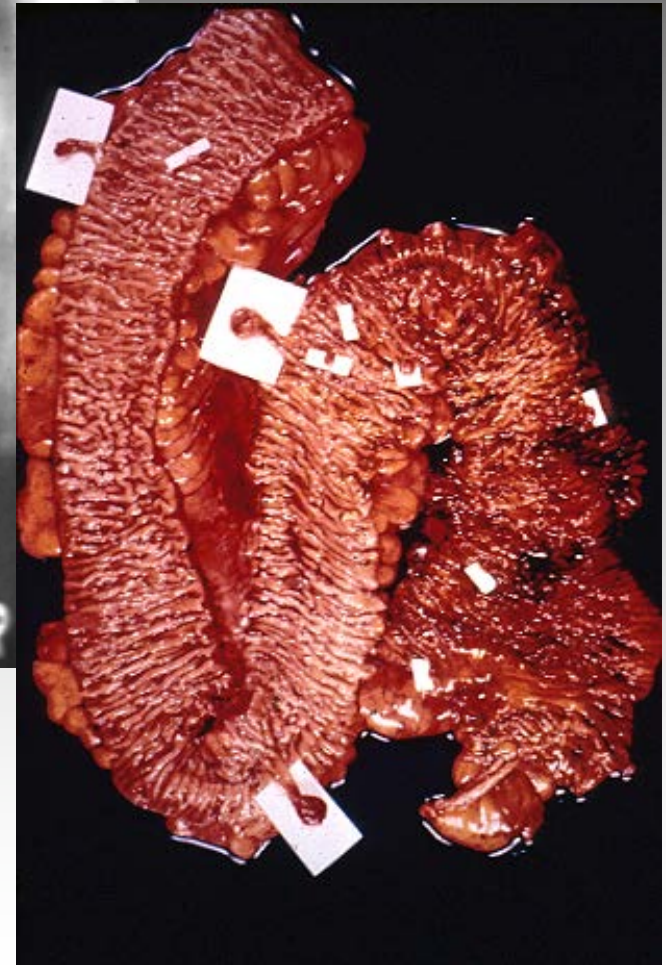
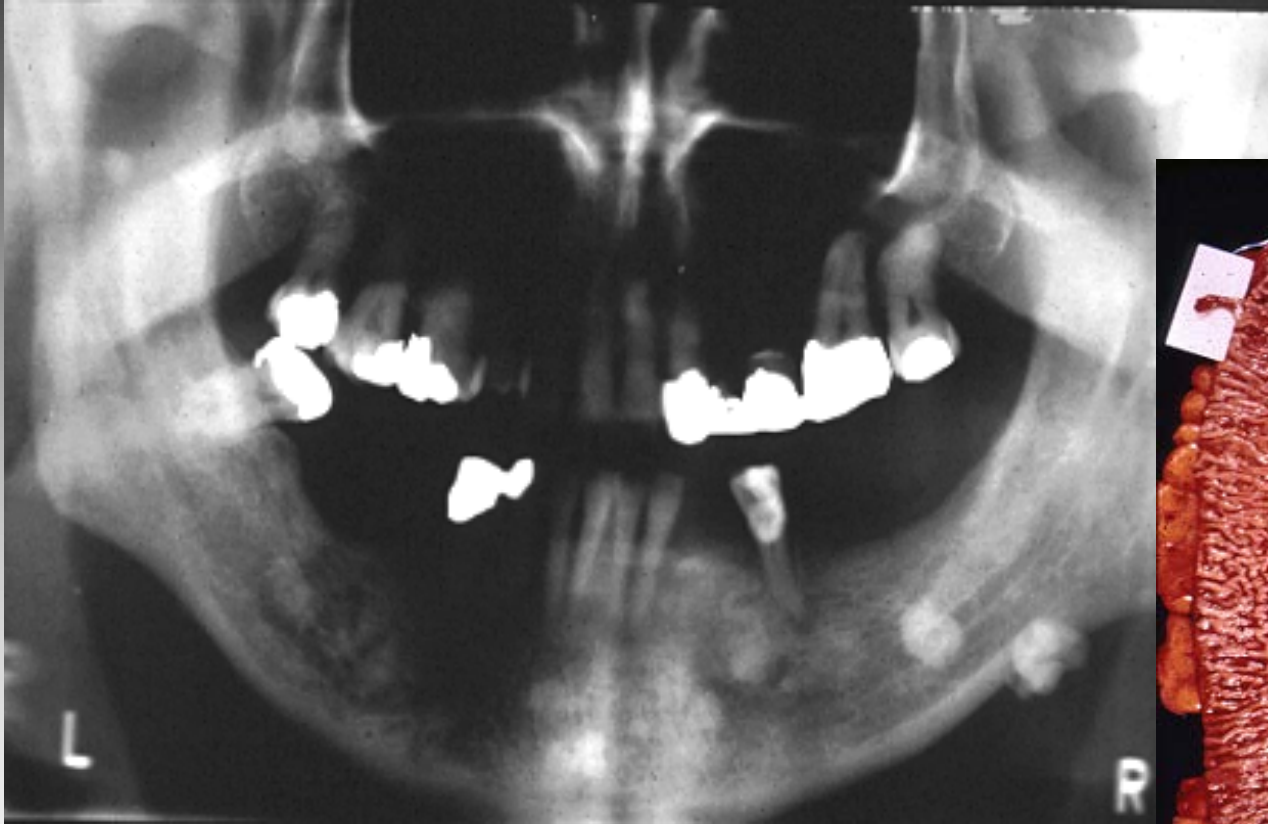Exostoses

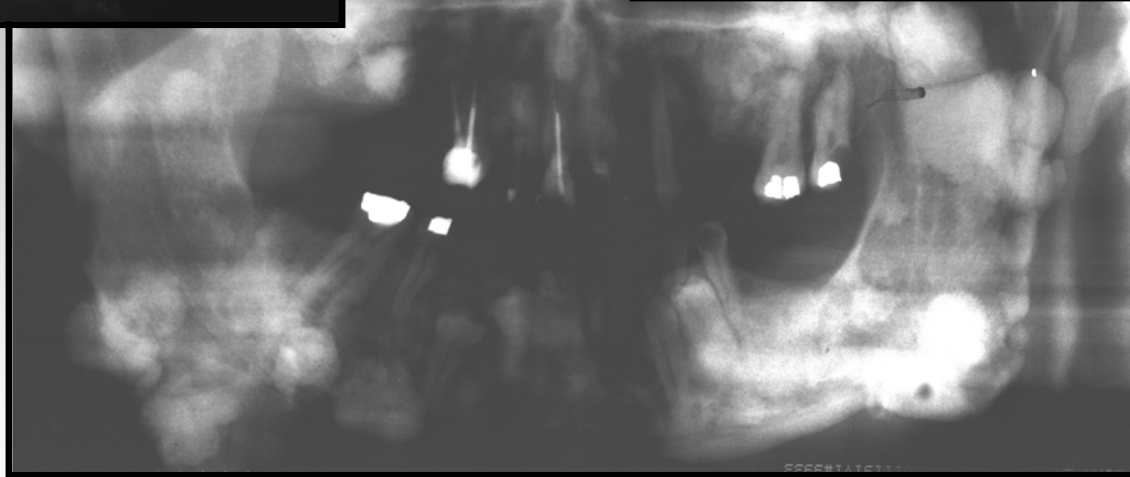
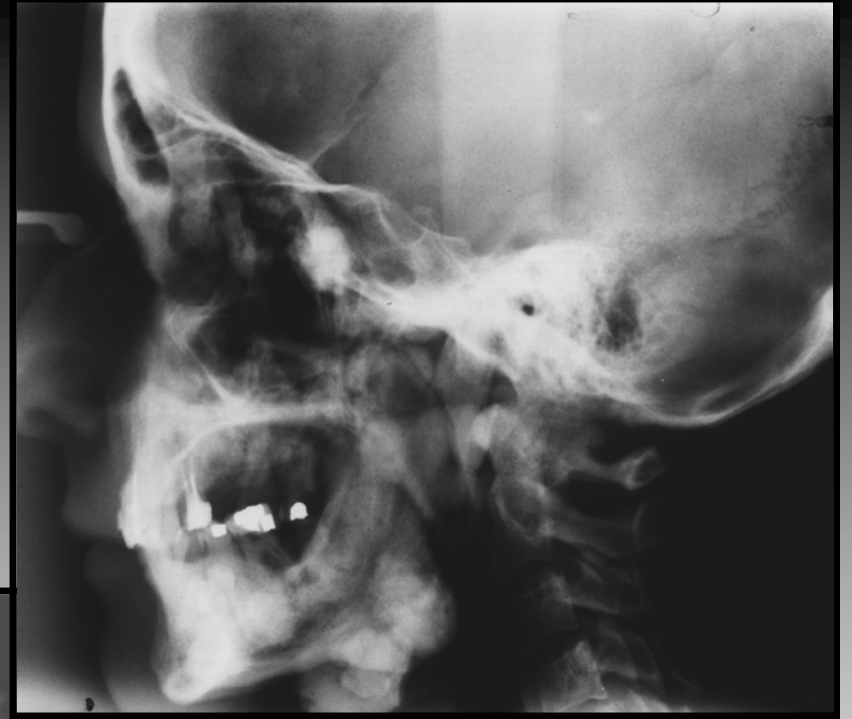
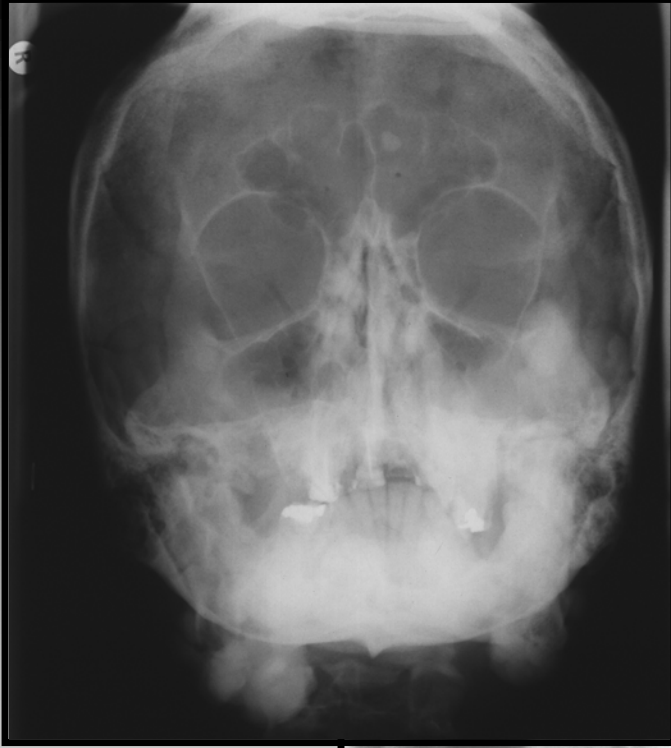
The Gardner Syndrome

- Intestinal Polyposis Syndrome
- Adenomatous Polyps
- APC Gene Mutation
- Adenocarcinoma, Colon
- Multiple Osteomas
- Supernumerary Teeth
- Cutaneous Desmoids

Gardner Syndrome (Osteomas)





Gardner Syndrome